



Annalise Enterprise

User Guide

Publication date 2024-06
OPT-PRM-027 v7
Copyright © 2024 ANNALISE-AI PTY LTD

Product	Release
Annalise Enterprise	3.8 which includes: <ul style="list-style-type: none">• Annalise Viewer version 3.6• Annalise Backend version 3.8• Annalise Integration Adapter version 3.8
Annalise Web Viewer	1.2



Annalise Enterprise



ANNALISE-AI PTY LTD
Level P
24 Campbell St
Sydney NSW 2000
AUSTRALIA
www.annalise.ai
support@annalise.ai

Table of Contents

Regulatory information	1
Regulatory information	2
Product overview	3
Product use	4
Intended purpose	4
Indications for use	4
Intended user	4
Intended patient population	4
Contraindications	4
Warning	5
Annalise product compatibility	5
Installation and system requirements	5
About Annalise Enterprise	6
Product description	6
Annalise Viewer	6
Annalise Secondary Capture	6
Worklist Triage	7
Artificial intelligence (AI) algorithms	7
Supported scan types	8
Operating points	8
Security features	8
Annalise Viewer	9
Annalise Viewer functions	10
Main components	10
Image Panel: CTB	11
Image Panel: CXR	12
Findings List	13
Study Details Panel (CXR only)	14
Feedback mode	15
Image Panel functions	17
Findings List functions	19
Study Details Panel functions (CXR only)	22
Feedback mode functions	23
Getting started: Annalise Viewer	25
Run Annalise Viewer Adapter	25
Launch Annalise Viewer	25
Access Annalise Enterprise (using single sign-on)	26
Access Annalise Enterprise (using legacy access)	28
Access initial functions	29
Set user preferences	31
Using the Annalise Viewer	33
Review AI findings	33
Provide feedback	36
Annalise Secondary Capture	38
Annalise Secondary Capture functions	39
Main components	39
Info bar	39
Summary Panel	40
Finding Panel	43
Info bar functions	46
Summary Panel functions	47

Finding Panel functions	49
Getting started: Annalise Secondary Capture	52
Access Annalise Secondary Capture	52
View the results	52
Using Annalise Secondary Capture	53
Review AI findings	53
Interpret the confidence level	55
Annalise Web Viewer	56
About Annalise Web Viewer	57
Overview	57
Annalise Web Viewer functions	58
Main components	58
Results List	58
Study Viewer	59
Study Viewer: Image Panel (CTB)	60
Study Viewer: Image Panel (CXR)	61
Study Viewer: Findings List	62
Results List functions	63
Study Viewer functions	65
Getting started: Annalise Web Viewer	70
Launch Annalise Web Viewer	70
Access studies in the Results List	70
Sort studies	72
Filter studies	73
View the results	74
Using the Annalise Web Viewer	75
Review AI findings	75
Troubleshooting and support	78
Troubleshooting	79
Problems and solutions	79
Support	86
Support and feedback	86
Symbol glossary	86
Appendices	87
Findings list	88
Annalise CXR findings list	88
Annalise CTB findings list	97

Regulatory information

Regulatory information

Annalise Enterprise

EC	REP
----	-----

QualRep Services B.V.
Utrechtseweg 310 - Bldg B42
NL-6812 AR Arnhem
THE NETHERLANDS

India Authorised Representative

Asia Actual India (OPC) Pvt. Ltd.
523A, Tower A, Spaze-I-Tech Park
Sector 49, Gurgaon, Haryana, 122018
INDIA
Import License Number: IMP/MD/2023/000218

CH	REP
----	-----

QUNIQUE GmbH
Bahnhofweg 17
5610 Wohlen AG
SWITZERLAND

Indonesia Authorised Representative

PT ARQon Solusi Medika
Rukan Niaga Gunung Sahari B-2
JakPus 10720
INDONESIA
Registration number: 21501321177

New Zealand Sponsor

AA-Med NZ Ltd.
Level 7, 54 Gill Street
New Plymouth 4310
NEW ZEALAND

Malaysia Authorised Representative

ARQon Medtech Sdn Bhd
No. 40-02, Jalan Adda 7
Taman Adda Heights, 81100, Johor Bahru, Johor
MALAYSIA
Registration number: GA7499322-108996

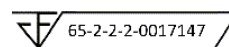
UK Responsible Person

Qserve Group UK Ltd.
282 Farnborough Road
GU14 7NA, Farnborough
UNITED KINGDOM

Thailand Authorised Representative

Asia Actual (Thailand) Co., Ltd.
8 T-One Building, Room No. 15-102
15th Floors, Soi Sukhumvit 40
Sukhumvit Road, Phra Khanong, Khlong Toei
BANGKOK 10110

Registration number:



Annalise Web Viewer

UK Responsible Person

Qserve Group UK Ltd.
282 Farnborough Road
GU14 7NA, Farnborough
UNITED KINGDOM

India Authorised Representative

Asia Actual India (OPC) Pvt. Ltd.
523A, Tower A, Spaze-I-Tech Park
Sector 49, Gurgaon, Haryana, 122018
INDIA
Registration Number: Annali-AUS/I/MD/017403

Product overview

Product use

Intended purpose

Annalise Enterprise is a medical device intended to assist clinicians with the interpretation of radiological imaging studies and provide notification of suspected findings.

Indications for use

Annalise Enterprise identifies suspected findings in:

- digitised (CR) or digital (DX) chest X-ray studies taken in the anterior-posterior (AP) or posterior-anterior (PA) and optionally lateral (LAT) orientations of adult patients
- non-contrast brain CT scans (brain kernel) of adult patients

For chest X-ray (CXR), the device improves the detection of radiological findings visible on chest X-rays. For CT Brain (CTB), the device improves the detection of radiological findings visible on non-contrast CT brain scans.

The device identifies 124 CXR findings and 130 CTB findings (as defined in the [Findings list, page 88](#)).

The device is used on a PC workstation in conjunction with a medical imaging viewer (i.e. PACS).

The device may also be configured to provide input to worklist software to assist with notification and triaging. The device identifies studies with selected findings and communicates these studies to the worklist software which enables triaging of the worklist and notification.

Intended user

The device is intended to be used by trained clinicians who are qualified to interpret chest X-rays and/or brain CT scans as part of their scope of practice.

Intended patient population

The intended population is:

- **CXR:** Patients who are 16 years or older
- **CTB:** Patients who are 18 years or older

Contraindications

The device:

- is not intended to provide direct diagnosis
- is not to be used on patients under the age of 16 years for CXR and under the age of 18 years for CTB
- does not enable an increase in the clinician's scope of practice

Warning



Qualified clinicians who interpret chest X-rays and/or brain CT scans as part of their scope of practice hold ultimate responsibility for interpreting studies.

The clinician must review the Annalise Enterprise output concurrently with the original chest X-ray images or brain CT scans and all other relevant clinical information before making a clinical decision.

Annalise product compatibility

Annalise Enterprise Backend Services compatibility is as follows:

Release	Component	Version
v3.8	Annalise Viewer	3.6, 3.5, 3.4, 3.2, 3.1
	Annalise Integration Adapter	3.8, 3.7, 3.6, 3.4, 3.3, 3.2, 3.1

Release	Product	Version
v1.2	Annalise Web Viewer	1.2, 1.1, 1.0

Installation and system requirements

Refer to the *Annalise Enterprise Administration Guide* for details about system requirements and installation.

About Annalise Enterprise

Product description

Annalise Enterprise is a clinical decision support application which uses artificial intelligence (AI) algorithms to assist clinicians with the interpretation of radiological imaging studies. It is compatible with image and order management systems such as picture archiving and communication systems (PACS) and radiological information systems (RIS).

The suspected findings are communicated to the clinician viewing the study by displaying the findings and associated localisation information to the clinician as they view the study in the PACS viewer.

Additionally, the device may be configured to provide input to worklist software to assist with notification and triaging. The device identifies studies with selected findings (as defined by the customer) and communicates these studies to the worklist software which enables triaging of the worklist and notification.

The output of Annalise Enterprise may be used in other products and/or modules to provide information to the intended users as specified in the Annalise Enterprise findings list.

Annalise Enterprise contains the following:

- Annalise Viewer
- Annalise Secondary Capture
- Worklist Triage

Annalise Viewer

The Annalise Viewer displays the AI results of adult chest X-ray studies and non-contrast CT brain studies (including findings and localisation information).

Annalise Secondary Capture

The Annalise Secondary Capture DICOM series is inserted into your PACS. When opened, the series displays the AI results of adult chest X-ray studies and non-contrast CT brain studies (including findings and localisation information).



Annalise Secondary Capture is not available in all regions.

Worklist Triage

Annalise Enterprise uses an AI algorithm to provide notification of selected findings for worklist prioritisation and triage.

Configuration options

Each organisation can specify the findings that will result in triage and the priority of each finding. The exact functionality available depends on the worklist software used.

Depending on the columns available in your worklist you can receive and display a study's AI priority in the worklist in either:

Column type	Details
A single 'Priority' column	Annalise Enterprise will only triage findings with the highest rank. This ensures that it will <u>never</u> decrease a study's existing priority in the worklist.
A dedicated 'AI priority' column	Annalise Enterprise can triage findings with all ranks in the dedicated AI priority column. This ensures that any existing priorities are not changed.



Contact the Annalise.ai Professional Services Team for assistance with your preferred configuration.

Artificial intelligence (AI) algorithms

The Artificial Intelligence (AI) algorithms used in the device are convolutional neural networks trained on over 750,000 CXR and 200,000 CTB imaging studies.

These algorithms use deep-learning techniques to:

- identify suspected radiological findings
- highlight the relevant areas of interest (display localisation) for a subset of findings, and
- identify laterality.

The images used to train these algorithms were sourced from datasets with a range of patient demographics and technical characteristics, including different X-ray and CT manufacturers and machines.

Supported scan types

Annalise Enterprise supports the following scan types:

CXR	CTB
<ul style="list-style-type: none"> • minimum one frontal (AP/PA) • up to three images in total 	<ul style="list-style-type: none"> • axial (coronal and sagittal views are generated by the axial view) • slice thickness up to and including 1.5 mm • non-contrast CT brain scans • brain reconstruction kernel (or similar) • up to 1,000 images



If a study contains more than three CXR images, the AI model will select a combination of the best three frontal/lateral images.

Operating points

Operating points for each finding are defined by your organisation during deployment (with assistance from Annalise.ai).

If you need to adjust an operating point for your organisation, contact your internal IT support team who can then request adjustments from Annalise.ai.

Security features

Annalise Enterprise includes security features which protect against unauthorised access and data modification.

These features ensure the secure authentication and encryption of sensitive data when transmitted between:

- the Annalise Integration Adapter and the Annalise Backend
- the Annalise Viewer and the Annalise Backend
- the PACS Image Viewer and the Annalise Viewer (available when using the HTTPS interface)

It also includes the encryption of sensitive data stored in the Annalise Backend.

Annalise Viewer

Annalise Viewer functions

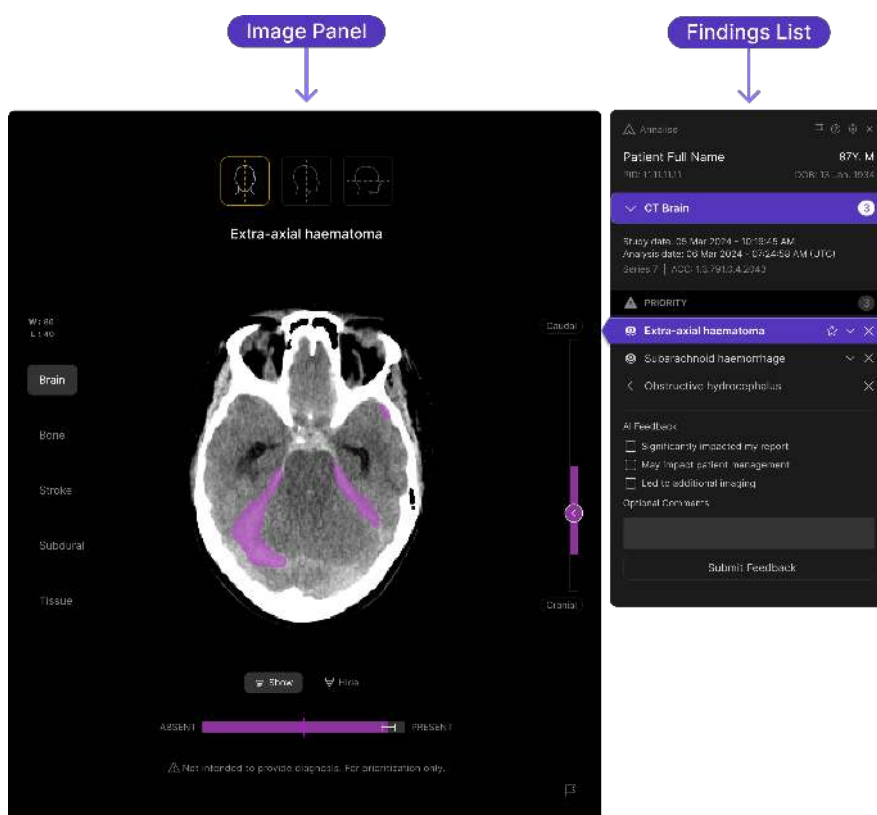
Overview

The following section outlines the functions available on the Annalise Viewer for CXR and CTB studies.

If your organisation has enabled the feedback function, extra functions will display when you are in 'feedback mode'. See [Feedback mode, page 15](#).

Main components

The Annalise Viewer includes the Image Panel and the Findings List.



For further details see:

- [Image Panel: CTB, page 11](#)
- [Image Panel: CXR, page 12](#)
- [Findings List, page 13](#)
- [Study Details Panel \(CXR only\), page 14](#)
- [Feedback mode, page 15](#)

Image Panel: CTB

Components and functions of the Image Panel (for CTB studies) are shown below.

Depending on the study's findings, the study may display localisation or laterality. The study in this example includes localisation.

See [Image Panel functions, page 17](#).

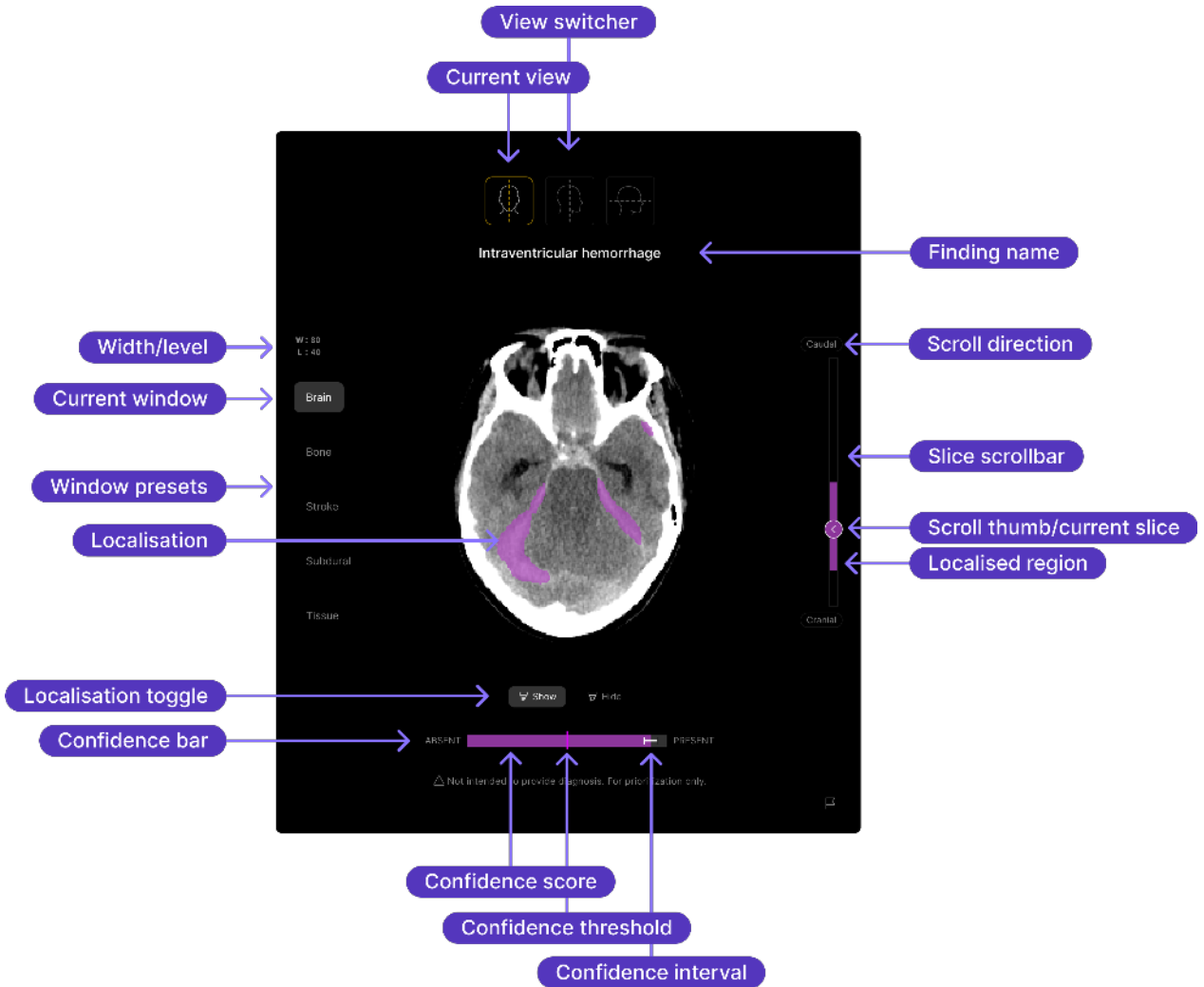
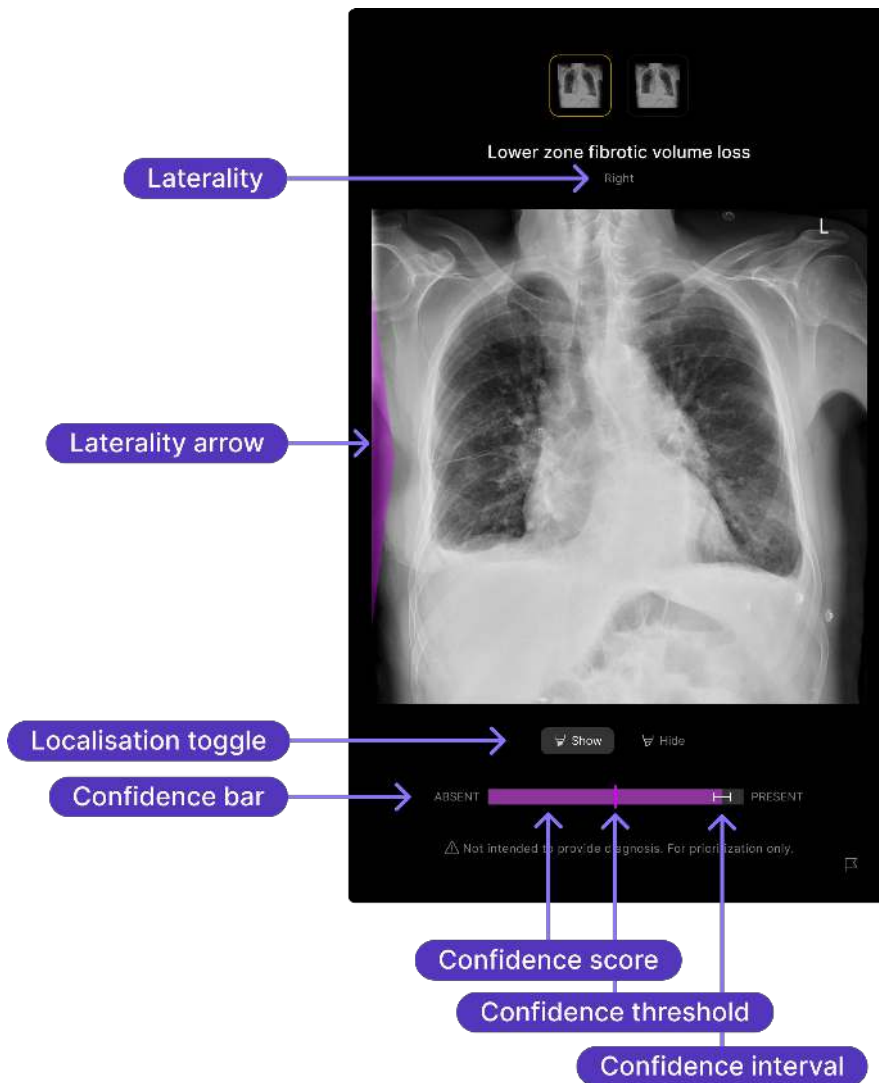


Image Panel: CXR

Components and functions of the Image Panel (for CXR studies) are shown below.

Depending on the study's findings, the study may display localisation or laterality. The study in this example includes laterality.

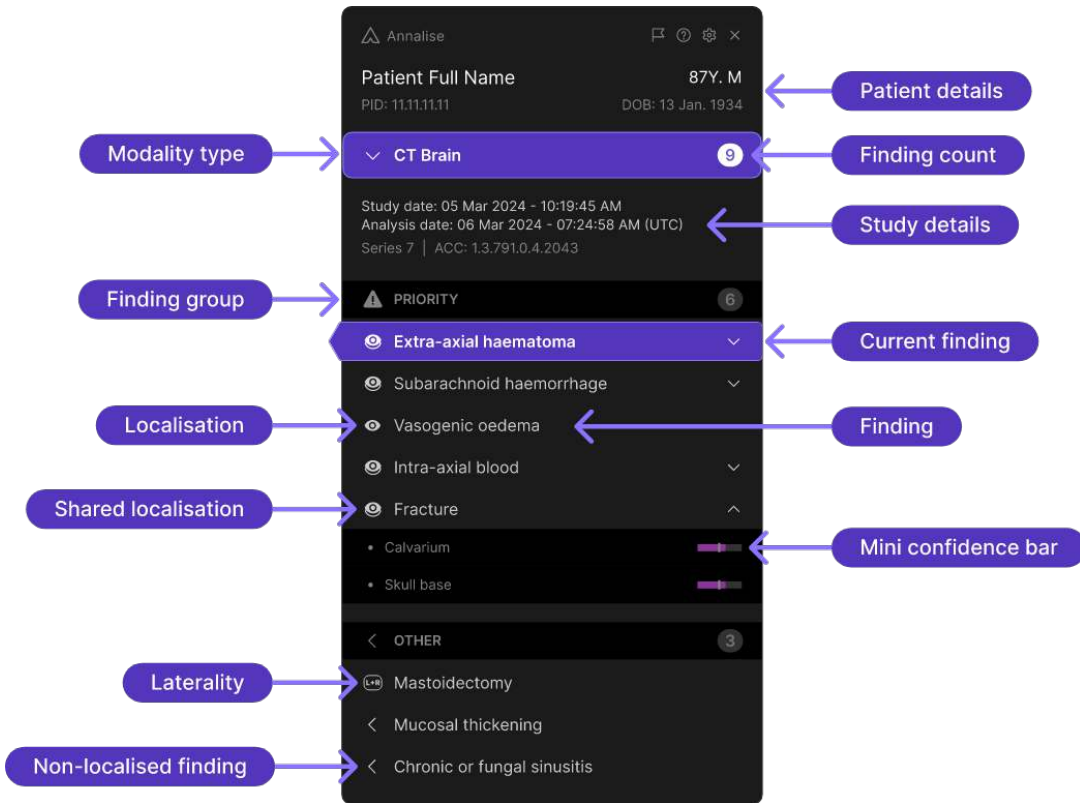
See [Image Panel functions, page 17](#).



Findings List

Components and functions of the Findings List are shown below.

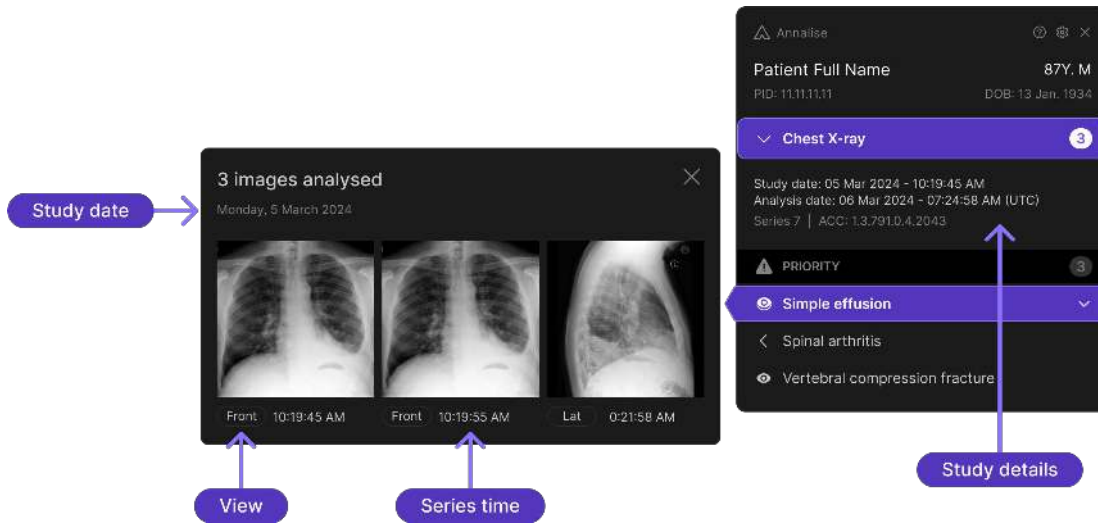
See [Findings List functions, page 19](#).



Study Details Panel (CXR only)

Components and functions of the Study Details Panel are shown below.

See [Study Details Panel functions \(CXR only\)](#), page 22.

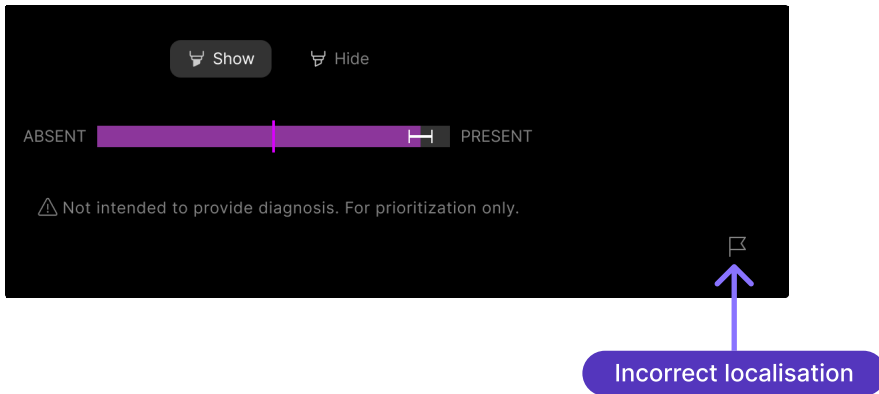

Feedback mode

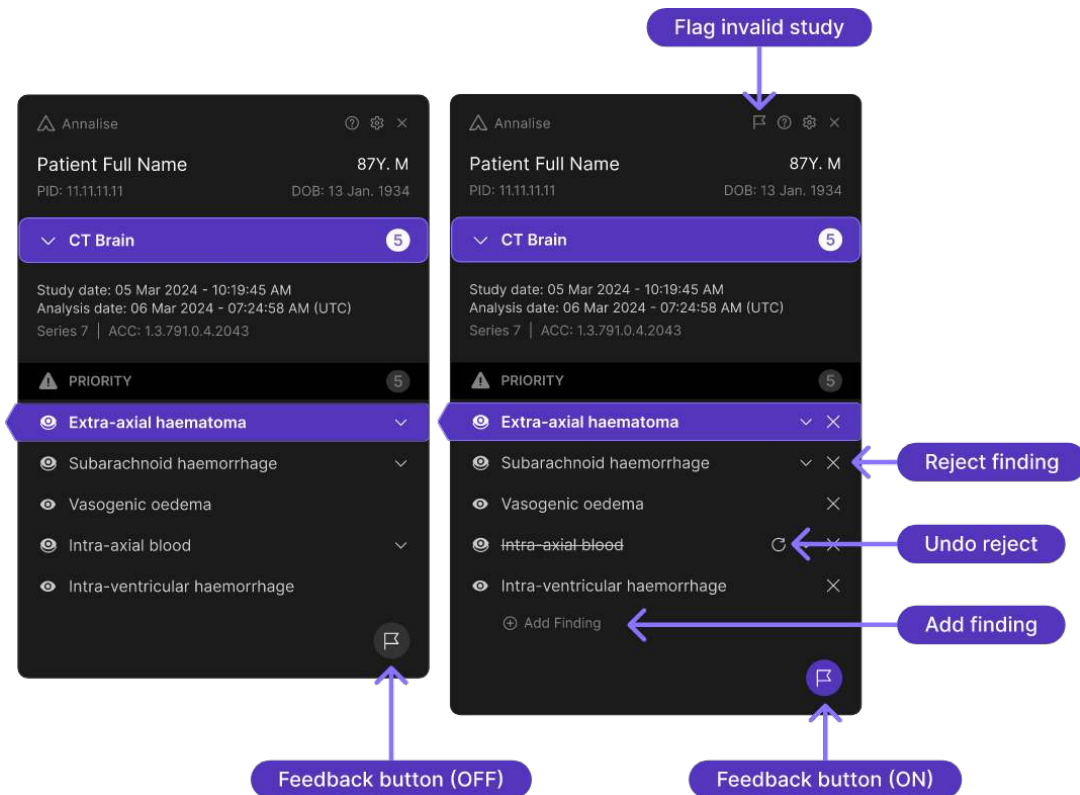
If the feedback function has been enabled by your organisation, some or all of the following options will display, depending on the type of feedback enabled.

See [Feedback mode functions, page 23](#).

Feedback mode: Image Panel



Feedback mode: Findings List (AI model feedback)



Feedback mode: Findings List (trial feedback)

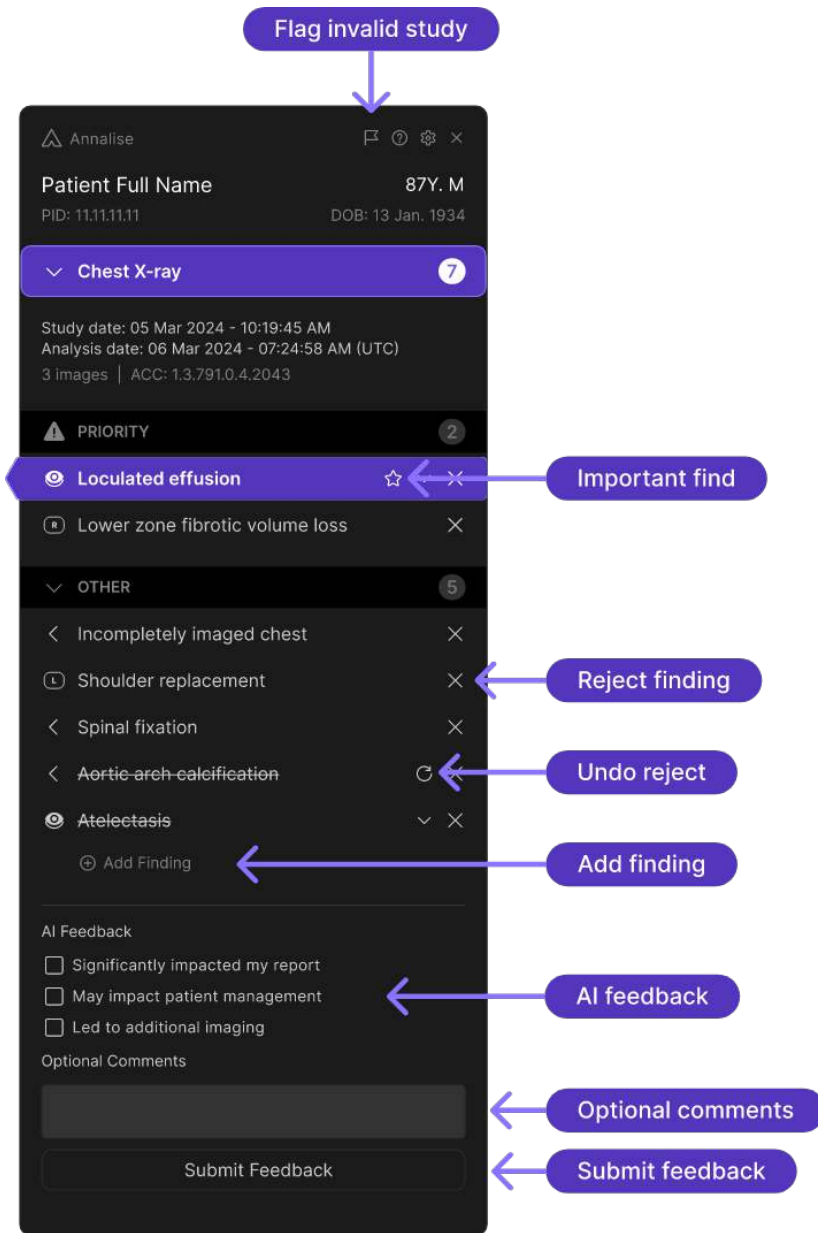



Image Panel functions

The Image Panel is located on the left of the Findings List.

It displays the current image associated with the selected finding, including any localisation or laterality related to the finding (and its confidence level). It also enables you to access different views of the study.

The following functions display on the Image Panel:

Function	Details				
View switcher	<p>The View switcher icons enable you to switch between image views.</p> <p>The following views are available:</p> <table border="1"> <tbody> <tr> <td>CXR</td> <td> <ul style="list-style-type: none"> • Frontal • Lateral (may not be present if not processed) </td> </tr> <tr> <td>CTB</td> <td> <ul style="list-style-type: none"> • Axial • Sagittal • Coronal </td> </tr> </tbody> </table> <p>The active view is highlighted.</p>	CXR	<ul style="list-style-type: none"> • Frontal • Lateral (may not be present if not processed) 	CTB	<ul style="list-style-type: none"> • Axial • Sagittal • Coronal
CXR	<ul style="list-style-type: none"> • Frontal • Lateral (may not be present if not processed) 				
CTB	<ul style="list-style-type: none"> • Axial • Sagittal • Coronal 				
Finding name	The Finding name displays the name of the finding selected in the Findings List.				
Width/level (CTB only)	<p>The Width/level indicates the predetermined width and level of the selected greyscale spectrum:</p> <ul style="list-style-type: none"> • W – indicates window width • L – indicates window level 				
Window presets (CTB only)	<p>Window presets enable you to view the following pre-configured options (for CTB studies):</p> <ul style="list-style-type: none"> • Brain • Bone • Stroke • Subdural • Tissue <p>When you select an option, the associated width/level values display (see Width/level, above).</p> <p>The active window is highlighted.</p>				
Slice scrollbar (CTB only)	<p>The Slice scrollbar enables you to scroll through all available slices for the current CTB study (see Scroll thumb/Current slice, below).</p> <p>If localisation is associated with the finding, the purple areas in the scrollbar indicate the areas of localisation in the study.</p>				
Scroll thumb/Current slice (CTB only)	<p>The Scroll thumb/Current slice enables you to scroll through the images. It also indicates the current slice position in the Slice scrollbar.</p>				
Scroll direction (CTB only)	<p>The Scroll direction displays at both ends of the Slice scrollbar.</p> <p>These indicators show the direction you are moving in as you scroll through the images.</p>				

Function	Details
Localisation	If localisation is associated with the finding, it will display as a purple overlay over the relevant area in the image.
Laterality	If localisation cannot be localised to a specific area, a purple Laterality arrow will indicate laterality on the left, right (or bilateral) sides of the image.
Localisation toggle	<p>The Localisation toggle enables you to show or hide localisation for the current study.</p> <div style="border: 1px solid #ccc; border-radius: 10px; padding: 10px; background-color: #f0f0f0;"> <p> If you switch this option off, it will automatically switch on again as soon as you hover over either a Localisation or Laterality icon.</p> </div>
Confidence bar	<p>The Confidence bar provides a visual indication of the confidence of the AI model that a particular finding is present.</p> <p>It enables you to see the relationship between the Confidence threshold, the Confidence score and the 95% Confidence interval.</p>
Confidence score	<p>The purple area in the confidence bar shows the AI model's Confidence score.</p> <p>This score indicates the model's confidence that a finding is present.</p>
Confidence threshold	<p>The Confidence threshold (i.e. the operating point) is a fixed threshold that is compared with the AI model's Confidence score.</p> <p>A confidence score above the confidence threshold will result in the AI model determining that the finding is present.</p>
Confidence interval	<p>The 95% Confidence interval shows the AI model's degree of certainty about its Confidence score.</p> <p>The smaller the distance between the confidence interval endpoints, the higher the score certainty.</p>

Findings List functions

The Findings List is located on the right of the Image Panel.


It displays details about the patient and the modality as well as information about the current study and its associated findings.


By default, the findings display in order of clinical severity (as determined by Annalise.ai expert radiologists), but you can configure this order to meet your requirements.


The Findings List enables you to access:


- the **Help** and **Settings** functions, and
- other analysed images for CXR studies (see [Study Details Panel \(CXR only\), page 14](#))

The following functions display on the Findings List:

Function	Details
Patient details	<p>The following patient details display for the current study:</p> <ul style="list-style-type: none"> • Name • Age • Gender • Patient ID • Date of birth (DOB) <p> You can choose how you would like the patient's name to display (see Set user preferences, page 31).</p> <p>Your organisation may have configured the patient ID label and/or date format used in the Annalise Viewer. If so, the details you see may not match the images in this guide.</p>
Modality type	<p>The Modality type indicates the current modality (i.e. 'Chest X-ray' or 'CT Brain').</p> <p>It also displays the total number of findings for the current study.</p>

Function	Details								
Study details	<p>The Study details display the following:</p> <table border="1"> <tr> <td>Study date and time</td> <td>The date and time the X-ray/CT machine recorded the study.</td> </tr> <tr> <td>Analysis date and time</td> <td>The date and time the AI model processed the study.</td> </tr> <tr> <td>Study description</td> <td> <p>CTB: The series number within the current study and the series description.</p> <p>CXR: The number of other analysed images for the study.</p> <p>If the description is more than 64 characters, an ellipsis (...) will display at the end, indicating that there is further information in this field. If this occurs, hover your mouse over the ellipsis to see the full description.</p> </td> </tr> <tr> <td>Accession number</td> <td>A unique number used to identify a diagnostic report. All images within a study will have the same accession number.</td> </tr> </table> <p> Your organisation may have configured the date format used in the Annalise Viewer. If so, the details you see may not match the images in this guide.</p>	Study date and time	The date and time the X-ray/CT machine recorded the study.	Analysis date and time	The date and time the AI model processed the study.	Study description	<p>CTB: The series number within the current study and the series description.</p> <p>CXR: The number of other analysed images for the study.</p> <p>If the description is more than 64 characters, an ellipsis (...) will display at the end, indicating that there is further information in this field. If this occurs, hover your mouse over the ellipsis to see the full description.</p>	Accession number	A unique number used to identify a diagnostic report. All images within a study will have the same accession number.
Study date and time	The date and time the X-ray/CT machine recorded the study.								
Analysis date and time	The date and time the AI model processed the study.								
Study description	<p>CTB: The series number within the current study and the series description.</p> <p>CXR: The number of other analysed images for the study.</p> <p>If the description is more than 64 characters, an ellipsis (...) will display at the end, indicating that there is further information in this field. If this occurs, hover your mouse over the ellipsis to see the full description.</p>								
Accession number	A unique number used to identify a diagnostic report. All images within a study will have the same accession number.								
Findings	<p>The suspected radiological findings detected by the AI model.</p> <p>If you hover over a finding in the Findings List:</p> <ul style="list-style-type: none"> • it will be highlighted purple in the Findings List, and • this finding will display on the Image Panel. <p>If the model detects that no findings are present, the Annalise Viewer will not contain any results (and the 'No AI findings detected' message will display).</p>								
Finding count	The Finding count that displays beside each finding group indicates the number of findings in that group.								

Function	Details								
Finding groups	<p>Finding groups are located on the Findings List.</p> <p>All findings are grouped according to status or type. Each finding has both a pre-defined display order and a group to which it belongs.</p> <p>The following default groups display:</p> <table border="1"> <tr> <td><i>Priority</i></td> <td>Findings in this group always display</td> </tr> <tr> <td><i>Other</i></td> <td></td> </tr> <tr> <td><i>User added</i></td> <td>This group displays if a user adds any additional findings</td> </tr> <tr> <td><i>Technical</i></td> <td>This group displays if one or more findings are classified as 'technical' (i.e. non-anatomical artefacts which occurred during the X-ray or scan)</td> </tr> </table> <p>Your organisation can request to configure the following:</p> <ul style="list-style-type: none"> • group names • displaying certain findings only • adding another group, and/or • determining the findings that display within each group. <div style="border: 1px solid #ccc; padding: 5px; margin-top: 10px;"> <p> As the first group will always contain findings that are more clinically relevant (regardless of whether it is called 'Priority' or has another name), it cannot be collapsed.</p> </div>	<i>Priority</i>	Findings in this group always display	<i>Other</i>		<i>User added</i>	This group displays if a user adds any additional findings	<i>Technical</i>	This group displays if one or more findings are classified as 'technical' (i.e. non-anatomical artefacts which occurred during the X-ray or scan)
<i>Priority</i>	Findings in this group always display								
<i>Other</i>									
<i>User added</i>	This group displays if a user adds any additional findings								
<i>Technical</i>	This group displays if one or more findings are classified as 'technical' (i.e. non-anatomical artefacts which occurred during the X-ray or scan)								
Localisation	<p>The Localisation icon displays when localisation is associated with the finding.</p> <p>See Localisation, page 18.</p>								
Shared localisation (CTB only)	<p>The Shared localisation icon displays when more than one finding shares the same localisation.</p> <p>These findings are grouped together to make it easier for the clinician to interpret the study. Each group includes a shared localisation 'title' (the finding name) and the associated findings displayed underneath (each with their own confidence levels - see Mini confidence bar), below.</p> <p>When you click this title, the shared localisation displays on the Image Panel.</p> <p>By default, each shared localisation group will be collapsed. Click the down arrow next to the title to display the associated findings or click the up arrow to collapse them.</p>								
Mini confidence bar (CTB only)	<p>The Mini confidence bar displays a smaller version of the confidence bar (but shows the confidence score and confidence threshold only).</p> <p>See Confidence bar, page 18.</p> <p>It displays next to the findings that are associated with a shared localisation only.</p>								

Function	Details
Laterality	<p>The Laterality icon displays if the finding is localised to left or right.</p> <p>The icon indicates the side (or sides) of the body to which the finding relates:</p> <ul style="list-style-type: none"> • L - Left • R - Right • L+R - Bilateral <p>See Laterality, page 18.</p>
Feedback button	<p>The Feedback button enables you to enter feedback mode and provide feedback about the AI model's performance.</p> <div style="border: 1px solid #ccc; padding: 5px; background-color: #f0f0f0;"> <p> This button only displays if the feedback function has been enabled for your organisation.</p> </div>

Study Details Panel functions (CXR only)

The Study Panel displays for CXR studies only. It enables you to view up to three of the images that were analysed to produce the AI findings.


Click the **Study details** area in the Findings List to display the Study Details Panel. See [Findings List, page 13](#).





Function	Details
Study details	See Study details, page 20 .
View	Indicates the view from which the image was taken.
Series time	Displays the time that the X-ray machine recorded the image.


Feedback mode functions

The following extra functions display on the Findings List and Image Panel while you are using the Annalise Viewer in 'feedback mode'. See [Provide feedback, page 36](#).

Feedback mode is only available if it has been enabled by your organisation.

 The feedback feature is not to be used for reporting product complaints. If you have a product complaint or urgent product feedback, see [Support and feedback, page 86](#).

Function	Details
Feedback button	<p>The Feedback button enables you to enter feedback mode and provide feedback about the AI model's performance.</p> <p> This button only displays if the feedback function has been enabled for your organisation.</p>
Flag invalid study	<p>The Flag invalid study button enables you to indicate that the study is either:</p> <ul style="list-style-type: none"> • <u>not</u> a CXR (for CXR studies), or • <u>not</u> an eligible series (for CTB studies).
Add finding	<p>The Add finding button enables you to add a finding that is missing from the study (i.e. was not identified by the AI model).</p>
Reject finding	<p>The Reject button enables you to reject a finding.</p>
Undo reject	<p>The Undo reject button enables you to reinstate a previously rejected finding in the Findings List.</p>
Important find	<p>The Important find ('star') button displays when you hover your mouse over a finding. It enables you to flag an important finding that the AI model has identified.</p> <p> This option is only available if your organisation has enabled the 'trial' feedback function.</p>
AI feedback	<p>The AI feedback questions enable you to provide specific feedback about the Annalise Viewer.</p> <p> This option is only available if your organisation has enabled the 'trial' feedback function. These questions can be customised for your organisation.</p>
Optional comments	<p>The Optional comments field enables you to provide additional feedback comments about the Annalise Viewer.</p> <p> This option is only available if your organisation has enabled the 'trial' feedback function.</p>

Function	Details
Submit feedback	<p>The Submit feedback button enables you to save and submit any feedback you have added.</p> <div data-bbox="464 369 1273 465"> This option is only available if your organisation has enabled the 'trial' feedback function.</div>
Incorrect localisation	<p>The Incorrect localisation button enables you to indicate that you believe localisation of the current finding is incorrect.</p>

Getting started: Annalise Viewer

Overview

This section shows you how to:

- run the Annalise Viewer Adapter (if required)
- launch the Annalise Viewer
- access Annalise Enterprise (via either single sign-on or legacy access)
- access initial functions, and
- set your user preferences.

Run Annalise Viewer Adapter

Depending on the type of PACS that you are using, you may need to run the Annalise Viewer Adapter to access the Annalise Viewer.

If you are using a Sectra IDS7 PACS, contact your system administrator to see whether the *Annalise Viewer Adapter for Sectra IDS7* has been installed on your computer.

For full details about installation and system requirements, refer to the *Annalise Viewer Adapter for Sectra IDS7 Administration Guide*.

Launch Annalise Viewer

You can choose whether you want the Annalise Viewer to display automatically when you view a study in the PACS/RIS or you can open it manually.



Your options may depend on the integration capabilities of your PACS/RIS.

Once open, the Annalise Viewer displays the AI results for the current study.

1. Open the PACS/RIS worklist.

If the Annalise Viewer doesn't automatically display, you can either:

Open Annalise Viewer manually	Open the Annalise Viewer via the Start menu on your computer.
Update settings to open Annalise Viewer automatically	See Automatically show findings, page 32 .

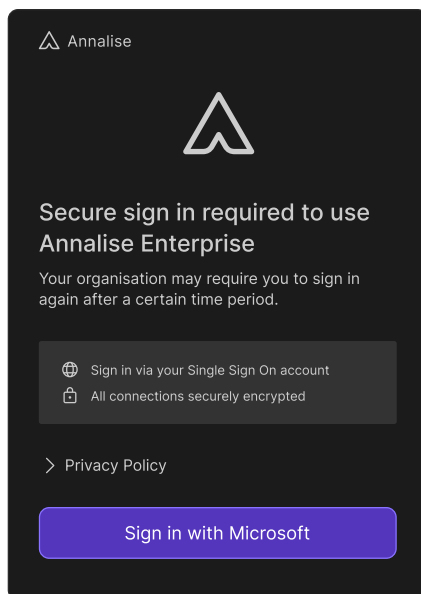
Access Annalise Enterprise (using single sign-on)

Single sign-on enables you to sign into both Annalise Enterprise and your Microsoft work account using a single set of credentials.

If your organisation has enabled single sign-on, you will need to enter your username and password via your internet browser through Microsoft.



If you want to view the Annalise.ai *Privacy Policy* before you log in, click **Privacy Policy** (then navigate back to the *Secure sign in* window once you have finished).



1. Click **Sign in with Microsoft**.
2. On the sign-in screen that displays, type your username and password (as provided by your organisation).

Once you have successfully signed in:

If this is the **first** time you have signed into Annalise Enterprise

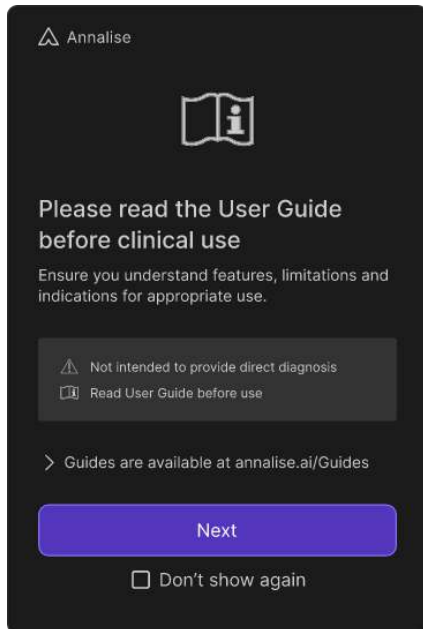
- a window will display, prompting you to read the *User Guide*
- go to [Read User Guide, page 27](#)

If you have signed in **previously** and chosen to hide the *User Guide* prompt

- the Annalise Viewer will automatically display the AI results for the current study

Read User Guide

Ensure that you read the *User Guide* so that you understand the features and limitations of the device as well as the indications for appropriate use.



1. Click the option to open the Annalise.ai guides, then read the *User Guide*.
2. If you don't want this window to display again, click to select the **Don't show again** checkbox.



If you select this checkbox, the next time you access Annalise Enterprise the Annalise Viewer will automatically display the AI results for the current study.

You can still access the *User Guide* via the **Help** button at the top of the Annalise Viewer. See [Access initial functions, page 29](#).

3. Once you have finished, click **Next**.

The Annalise Viewer will display the AI results for the current study.

Access Annalise Enterprise (using legacy access)

If your organisation has not enabled single sign-on, the following will occur when you first access Annalise Enterprise:

- a window will display prompting you to read the *User Guide*
- a message will prompt you to add your server settings (refer to the *Annalise Enterprise Administration Guide* for details)

Read User Guide

Ensure that you read the *User Guide* so that you understand the features and limitations of the device as well as the indications for appropriate use.

1. Click the option to open the Annalise.ai guides, then read the *User Guide*.
2. If you don't want this window to display again, click to select the **Don't show again** checkbox.



If you select this checkbox, the next time you access Annalise Enterprise the Annalise Viewer will automatically display the AI results for the current study.

You can still access the *User Guide* via the **Help** button at the top of the Annalise Viewer. See [Access initial functions, page 29](#).

3. When you have finished, click **Next**.

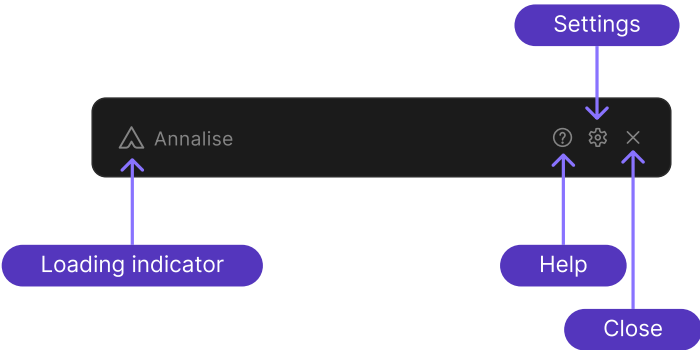
The Annalise Viewer will display the AI results for the current study.

Access initial functions

Once open, the Annalise Viewer will display the AI results for the current study.

Study loading

The following will display (and the loading indicator will spin) while the study is loading:




Study loaded

Once the study has loaded, the Findings List on the Annalise Viewer will either be collapsed or expanded, depending on the **Settings** options you choose.

See [Automatically show findings, page 32](#).

Findings List collapsed	Findings List expanded

Initial functions

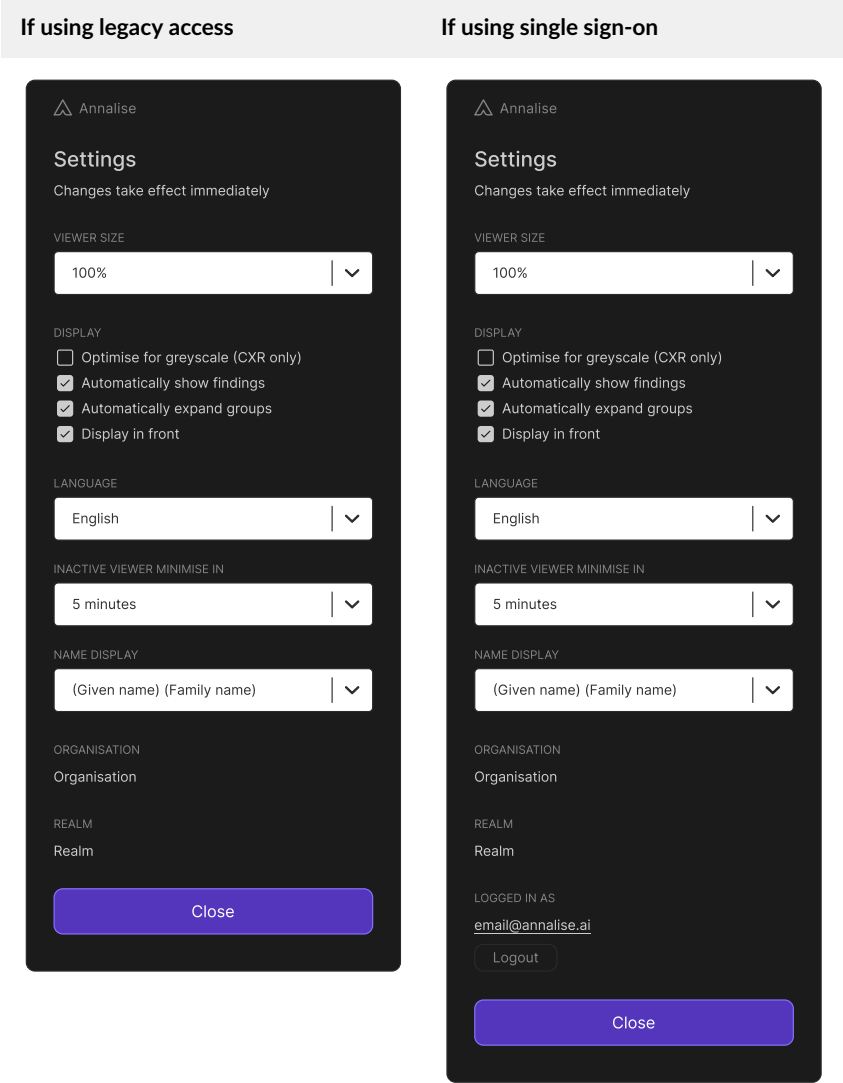
Action	Details
Loading indicator	When you first launch the Annalise Viewer, the Loading indicator will spin to indicate that the study is loading.
Access Help	<p>Click the Help button to:</p> <ul style="list-style-type: none"> • view the Annalise Viewer version and UDI • access the related <i>User Guide</i>, <i>Performance Specifications</i>, <i>Legal Notices</i> and <i>Privacy Policy</i> <p>Click the Close button to return to the Annalise Viewer.</p>
Set user preferences	<p>Click the Settings button to update your user preferences. See Set user preferences, page 31.</p> <div style="border: 1px solid #ccc; border-radius: 10px; padding: 10px; background-color: #f0f0f0;"> <p> If you are using legacy access and need to update your server settings, contact the Annalise.ai Professional Services Team for assistance.</p> </div> <p>Click the Close button to return to the Annalise Viewer.</p>
Close viewer	<p>Click the Close button to minimise the Annalise Viewer so that it displays on your task bar.</p> <p>The viewer will automatically re-open when there are new AI findings to display.</p>
Move viewer	To move the Annalise Viewer to another location or screen, click the viewer then drag it to the required position.
Close application	To close the application, right click the Annalise icon on your task bar then select Quit .

Set user preferences

Follow these steps to access the *Settings* screen to select your user preferences.

- 1. Click the **Settings** button at the top right of the Annalise Viewer.

The *Settings* screen displays.



2. Select your user preferences.

If you are using single sign-on, you can also:

- view the email of the user who is currently logged in, and
- click **Logout** to log out of Annalise Enterprise.

Option	Details
Viewer size	Click to select the size that you want the viewer to display on your screen.
Optimised for greyscale (CXR only)	Enables you to optimise the greyscale image: <ul style="list-style-type: none"> • if selected, the user interface will remove reliance on colours to display findings (your CXR radiography monitor may be greyscale only) • if <u>not</u> selected, the user interface will use colour to highlight findings
Automatically show findings	Enables you to automatically show findings when you are viewing a study: <ul style="list-style-type: none"> • if selected, the Findings List will automatically display the findings • if <u>not</u> selected (or if the automatic option is not available), you will need to manually expand the Findings List: <ul style="list-style-type: none"> • open the Annalise Viewer (see Open Annalise Viewer manually, page 25) • click the Modality type on the Findings List (see Modality type, page 19)
Automatically expand groups	Enables you to automatically expand all finding groups when the Findings List displays: <ul style="list-style-type: none"> • if selected, all groups will be expanded • if <u>not</u> selected, only the 'Priority' findings group (or your organisation's equivalent) will be expanded <p>See Finding groups, page 21.</p>
Display in front	Enables you to display the Annalise Viewer in front of all other applications on your desktop.
Language	Select the relevant language to display.
Inactive viewer minimise in	Select the inactive time period after which the viewer will be automatically minimised.
Name display	You can choose how you would like the patient name to display: <ul style="list-style-type: none"> • (Given name) (Family name) • (Family name) (Given name) • (Family name), (Given name)
Organisation and Realm	<i>May be requested by your internal IT support team when troubleshooting.</i>
Logged in as (SSO only)	<i>Displays the email address used to log into Annalise Enterprise.</i>

3. When you have finished, click **Close** to return to the Annalise Viewer.

Using the Annalise Viewer

Review AI findings

The Annalise Viewer displays the suspected radiological findings for a study in the Findings List (the results that display depend on the configuration set by your organisation).

This section shows you how to:

- verify the patient's details
- review the findings
- interpret the confidence level of each finding

Verify patient details

1. Launch the Annalise Viewer.

See [Launch Annalise Viewer, page 25](#).

2. To verify the patient's details, check that the Patient ID and Accession No. (ACC) on the Findings List match those on the study loaded in the PACS viewer.




Your organisation may have configured the patient ID label used in the Annalise Viewer. If so, the details you see may not match the images in this guide.

Review the findings

Multiple findings with varying degrees of confidence may display. In these instances, it is important to use your clinical judgement when reviewing all findings.

Use the following functions to help you review the findings:

Function	Details			
Show images analysed for the current study	Select a finding in the Findings List to display it in the Image Panel.			
	<table border="1"> <tbody> <tr> <td>CXR studies</td> <td> <p>You can view both:</p> <ul style="list-style-type: none"> • the current image in the Image Panel, and • up to two other images that have been analysed for the current study (click the Study details on the Findings List to display these images) <p>See Study Details Panel (CXR only), page 14.</p> </td> </tr> <tr> <td>CTB studies</td> <td> <p>Click and drag the Scroll thumb (or use your mouse wheel) to scroll through the images.</p> <p>See:</p> <ul style="list-style-type: none"> • Scroll thumb/Current slice, page 17 • Slice scrollbar, page 17 </td> </tr> </tbody> </table>	CXR studies	<p>You can view both:</p> <ul style="list-style-type: none"> • the current image in the Image Panel, and • up to two other images that have been analysed for the current study (click the Study details on the Findings List to display these images) <p>See Study Details Panel (CXR only), page 14.</p>	CTB studies
CXR studies	<p>You can view both:</p> <ul style="list-style-type: none"> • the current image in the Image Panel, and • up to two other images that have been analysed for the current study (click the Study details on the Findings List to display these images) <p>See Study Details Panel (CXR only), page 14.</p>			
CTB studies	<p>Click and drag the Scroll thumb (or use your mouse wheel) to scroll through the images.</p> <p>See:</p> <ul style="list-style-type: none"> • Scroll thumb/Current slice, page 17 • Slice scrollbar, page 17 			

Function	Details						
Switch between views	<p>On some clinical findings, the regions of interest may be highlighted on multiple views.</p> <p>To switch between views, click the View Switcher to navigate to other available views (the highlighted icon indicates the active view).</p> <p>For CTB studies, you can also use the Width/level to view the relevant pre-configured window presets.</p> <p>See:</p> <ul style="list-style-type: none"> • View switcher, page 17 • Width/level, page 17 						
Identify the number of findings present	<p>A number displays in the following locations to indicate the number of findings identified by the AI model:</p> <ul style="list-style-type: none"> • beside the Modality type (total number of findings), and • next to each findings group (total for that group). <p>See Finding count, page 20.</p> <p>Click the down arrow beside any findings with shared localisation to view all associated findings (see Shared localisation, page 21).</p>						
Switch localisation/ laterality option on or off	<p>To switch the localisation/laterality option on or off, click the Localisation toggle at the bottom of the Image Panel.</p> <p>See Localisation toggle, page 18.</p>						
Review regions of interest (ROI)	<p>If present, regions of interest (ROI) will be highlighted on the image displayed in the Image Panel.</p> <table border="1"> <tbody> <tr> <td>View localisation</td> <td> <p>If localisation is associated with a finding, a Localisation icon will display next to the finding name in the Findings List and a purple overlay will display on the image when you select the finding.</p> <p>For CTB studies, you can also use the Scroll thumb to scroll through the areas highlighted in purple on the Slice scrollbar.</p> </td> </tr> <tr> <td>View laterality</td> <td> <p>If laterality is associated with a finding, a Laterality icon will display next to the finding name in the Findings List and a purple arrow (or arrows) will display on the image when you select the finding.</p> </td> </tr> <tr> <td>Localisation does not display</td> <td> <p>If the AI model indicates that a finding is present and its location is obvious to the clinician, localisation will not display for that finding (and the Localisation icon will not show in the Findings List).</p> <p>To check which findings display localisation, see the Findings list, page 88.</p> </td> </tr> </tbody> </table> <div style="border: 1px solid #ccc; border-radius: 10px; padding: 10px; margin-top: 10px;"> <p> The Localisation toggle must be switched on to view localisation or laterality. See Localisation toggle, page 18.</p> </div>	View localisation	<p>If localisation is associated with a finding, a Localisation icon will display next to the finding name in the Findings List and a purple overlay will display on the image when you select the finding.</p> <p>For CTB studies, you can also use the Scroll thumb to scroll through the areas highlighted in purple on the Slice scrollbar.</p>	View laterality	<p>If laterality is associated with a finding, a Laterality icon will display next to the finding name in the Findings List and a purple arrow (or arrows) will display on the image when you select the finding.</p>	Localisation does not display	<p>If the AI model indicates that a finding is present and its location is obvious to the clinician, localisation will not display for that finding (and the Localisation icon will not show in the Findings List).</p> <p>To check which findings display localisation, see the Findings list, page 88.</p>
View localisation	<p>If localisation is associated with a finding, a Localisation icon will display next to the finding name in the Findings List and a purple overlay will display on the image when you select the finding.</p> <p>For CTB studies, you can also use the Scroll thumb to scroll through the areas highlighted in purple on the Slice scrollbar.</p>						
View laterality	<p>If laterality is associated with a finding, a Laterality icon will display next to the finding name in the Findings List and a purple arrow (or arrows) will display on the image when you select the finding.</p>						
Localisation does not display	<p>If the AI model indicates that a finding is present and its location is obvious to the clinician, localisation will not display for that finding (and the Localisation icon will not show in the Findings List).</p> <p>To check which findings display localisation, see the Findings list, page 88.</p>						

Interpret the confidence level

A default confidence threshold for each finding will be provided for your organisation. For a finding to be considered present in the study, it must therefore have a score greater than this threshold.

For each finding, the AI model provides:



- a confidence score, and
- a 95% confidence interval.

This information is displayed on the Confidence bar in the Image Panel.

See:

- [Confidence bar, page 18](#)
- [Confidence score, page 18](#)
- [Confidence threshold, page 18](#)
- [Confidence interval, page 18](#)

Refer to the following examples:

Confidence level	Interpretation
Higher confidence	<ul style="list-style-type: none">• The confidence score is above the confidence threshold• Both confidence interval endpoints are above the confidence threshold• The AI model has a high confidence that the finding is present in the study 
Lower confidence	<ul style="list-style-type: none">• The confidence score is above the confidence threshold• The lower endpoint of the confidence interval is below the confidence threshold• The AI model may have some uncertainty that the finding is present in the study 

Provide feedback

The feedback function enables you to provide feedback about the AI model's performance.

Depending on the feedback mode you are using, you can:

- flag an incorrect study
- flag an incorrect localisation
- add missing findings
- reject findings (and reinstate previously rejected findings)
- mark findings as an 'important find'






The feedback feature is not to be used for reporting product complaints. If you have a product complaint or urgent product feedback, see [Support and feedback, page 86](#).

The following types of feedback are available:

Feedback mode	Usage
Trial feedback	<p>Usually enabled when you are using Annalise Enterprise as part of an evaluation during a trial period.</p> <ol style="list-style-type: none"> 1. Refer to the table below for feedback options. 2. To save and submit your feedback, click Submit feedback.
AI model feedback	<p>Your organisation can choose to switch this function on or off.</p> <ol style="list-style-type: none"> 1. If the feedback options don't automatically display, go to the bottom right of the Findings List and click the Feedback ('flag') button (see Feedback mode: Findings List (AI model feedback), page 15). 2. Refer to the table below for feedback options. 3. To save and submit your feedback, click the Feedback button again.

Feedback options

Option	Steps
Flag an incorrect study	<p>If a study is invalid, click the Flag invalid study ('flag') button at the top of the Findings List.</p> <p>To undo this action, click the button again to remove the flag.</p>
Flag an incorrect localisation	<p>If you feel that the localisation of the current finding is incorrect, click the Incorrect localisation button at the bottom right of the Image Panel.</p> <p>A flag will display to the right of the finding on the Findings List.</p> <p>To undo this action, click the button on the Image Panel again to remove the flag.</p>
Add a missing finding	<p>If a finding is missing from the study:</p> <ol style="list-style-type: none"> 1. Click Add Finding at the bottom of the Findings List. 2. Type the name of the finding in the Enter Finding field. <ul style="list-style-type: none"> • if the finding displays, click to select the finding • if the finding <u>doesn't</u> display, type the full name of the finding, then click Add New <p>The new finding will display under the <i>User added</i> finding group.</p> <p>See Finding groups, page 21.</p>
Reject an incorrect finding	<p>If you determine that an AI finding that displays in the Findings List is not present in the study, click the Reject button beside the finding name.</p> <p>The finding name will display as strikethrough text.</p>
Undo a rejected finding	<p>If you have rejected a finding but want to undo this action (and reinstate the finding in the Findings List), click the Undo Reject button beside the finding name.</p>
Mark a finding as an 'important find'	<p>If you determine that the AI model has identified an important finding that may otherwise have been missed, hover your mouse over the relevant finding and click the Important find ('star') button.</p> <div style="border: 1px solid #ccc; border-radius: 10px; padding: 5px; background-color: #f0f0f0; margin-top: 10px;"> <p> This option can only be used during trial feedback</p> </div>
Feedback questions	<p>Click to select any question/s if they apply.</p> <div style="border: 1px solid #ccc; border-radius: 10px; padding: 5px; background-color: #f0f0f0; margin-top: 10px;"> <p> This option can only be used during trial feedback. The questions can be customised for your organisation.</p> </div>
Provide extra comments	<p>Type any extra comments in the Optional Comments field.</p> <div style="border: 1px solid #ccc; border-radius: 10px; padding: 5px; background-color: #f0f0f0; margin-top: 10px;"> <p> This option can only be used during trial feedback</p> </div>

Annalise Secondary Capture

Annalise Secondary Capture functions

Overview

The following section outlines the functions available on Annalise Secondary Capture.

Main components

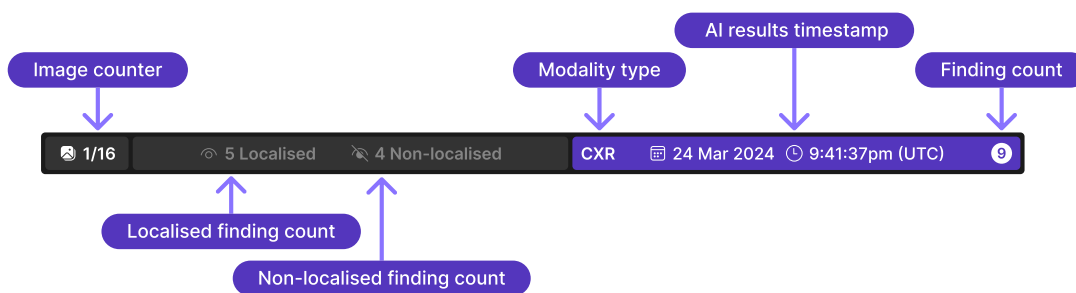
Annalise Secondary Capture includes the following:

- Info bar
- Summary Panel
- Finding Panel

Info bar

The Info bar displays at the top of all screens and includes information about the current study.

See [Info bar functions, page 46](#).



Summary Panel

The Summary Panel is the first panel that displays when you view Annalise Secondary Capture.

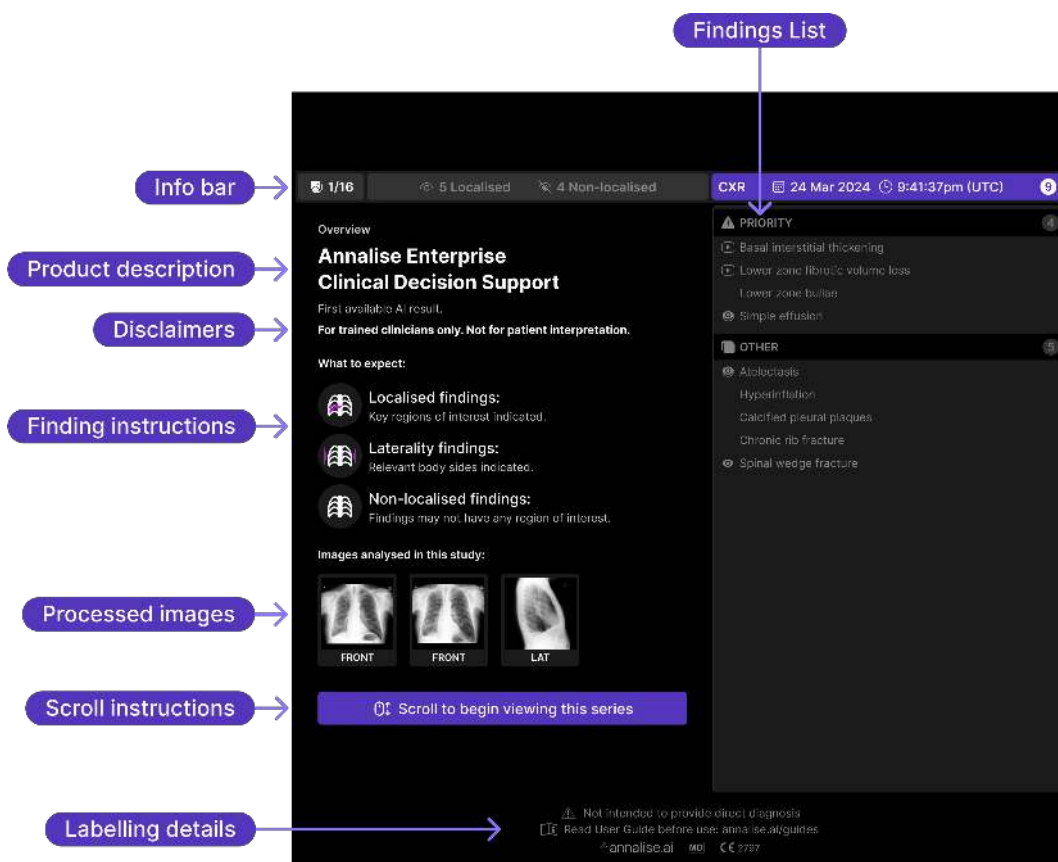
It includes instructions about using Annalise Secondary Capture and displays the images that were analysed for the current study.

It also displays the findings that have been identified by the AI algorithm.

See [Summary Panel functions, page 47](#).

Findings detected: CXR

The following example shows a CXR result in which findings have been detected.



Findings detected: CTB

The following example shows a CTB result in which findings have been detected.

The screenshot displays the Annalise Enterprise Clinical Decision Support interface. On the left, several callout boxes with arrows point to specific UI elements:

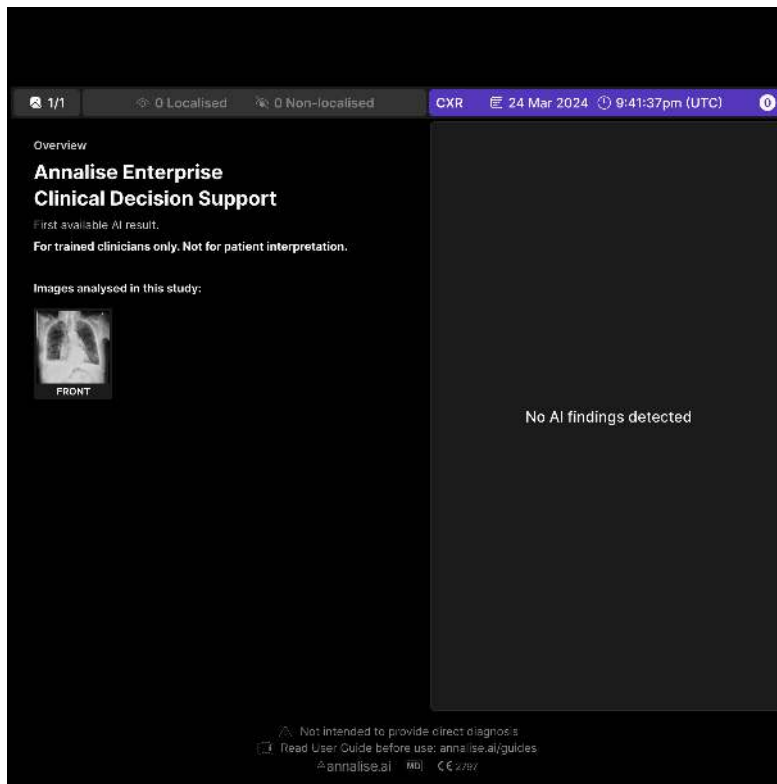
- Info bar:** Points to the top navigation bar showing '1/5', '3 Localised', '2 Non-localised', and 'CTB 24 Mar 2024 10:31:05pm (UTC)'.
- Product description:** Points to the header 'Annalise Enterprise Clinical Decision Support'.
- Disclaimers:** Points to the text 'First available AI result. For trained clinicians only. Not for patient interpretation.'
- Finding instructions:** Points to the 'What to expect' section, which includes:
 - Localised findings:** Key regions of interest indicated.
 - Laterality findings:** Relevant body sides indicated.
 - Non-localised findings:** Findings may not have any region of interest.
 - Single slice displayed per finding:** Use original series to review extent of each finding.
- Series analysed:** Points to the 'Series analysed in this study' section, showing 'Series Number: 4' and 'Series Description: Brain Head 0.5'.
- Scroll instructions:** Points to a button that says '0: Scroll to begin viewing this series'.
- Labelling details:** Points to the footer text: 'Not intended to provide direct diagnosis. Read User Guide before use: annalise.ai/guides. © annalise.ai 2024. CE 2797'.

The main content area on the right shows a list of findings under the heading 'CTB'. The findings are categorized into 'PRIORITY' and 'OTHER':

- PRIORITY (4):**
 - Acute infarct
 - Sulcal effacement
 - Vasogenic oedema
- OTHER (1):**
 - Mucosal thickening

No findings detected

The following example shows a study for which no findings have been detected.



Finding Panel

If findings are detected for a study, the Finding Panel displays as you scroll through the results.

The following will display on the Findings Panel:

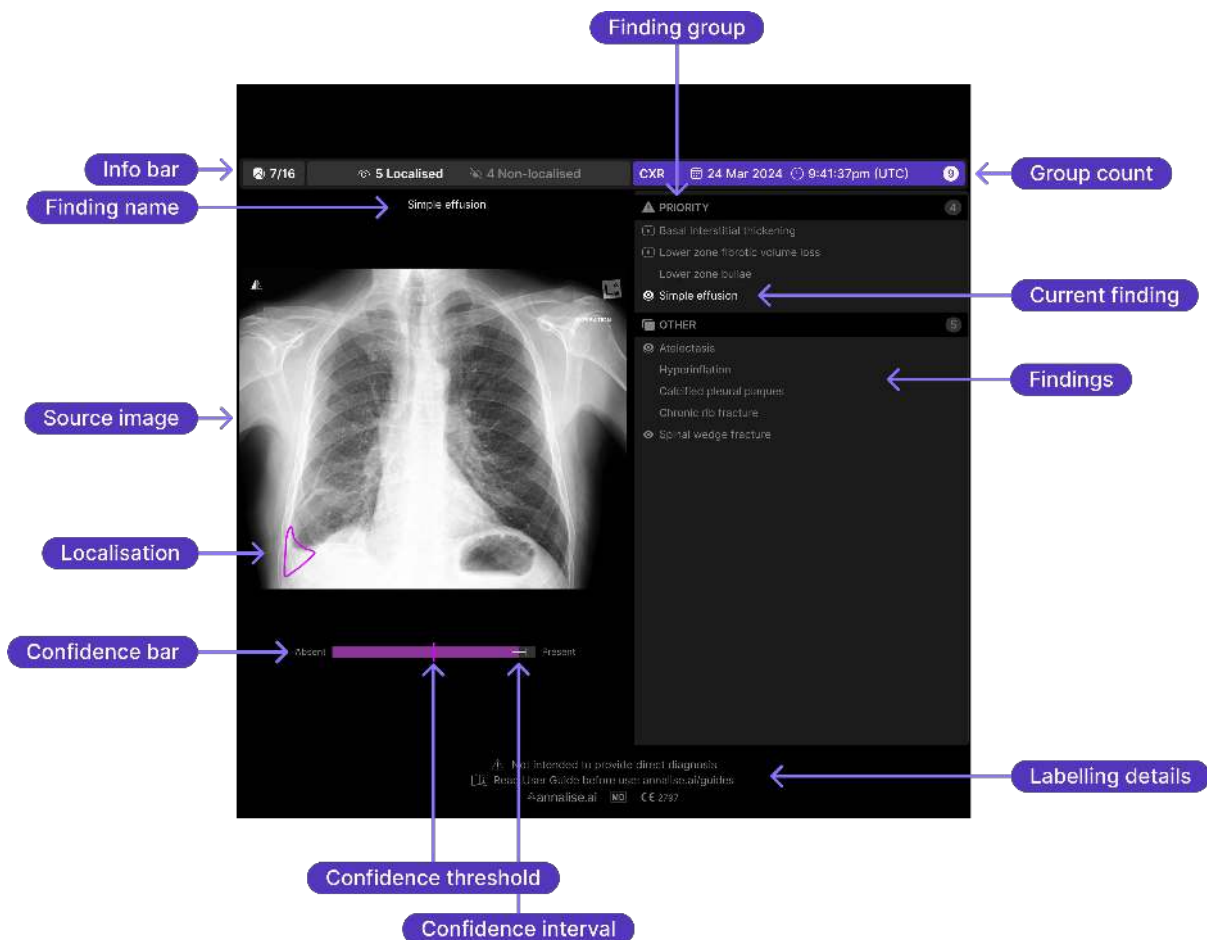
CXR	One or more images per finding (depending on the number of images analysed by the AI model).
CTB	One image per finding (findings with shared localisation will appear together on one image). See Shared localisation , page 50.

By default, the findings display in order of clinical severity (as determined by Annalise.ai expert radiologists) but you can configure this order to meet your requirements.

See [Finding Panel functions](#), page 49.

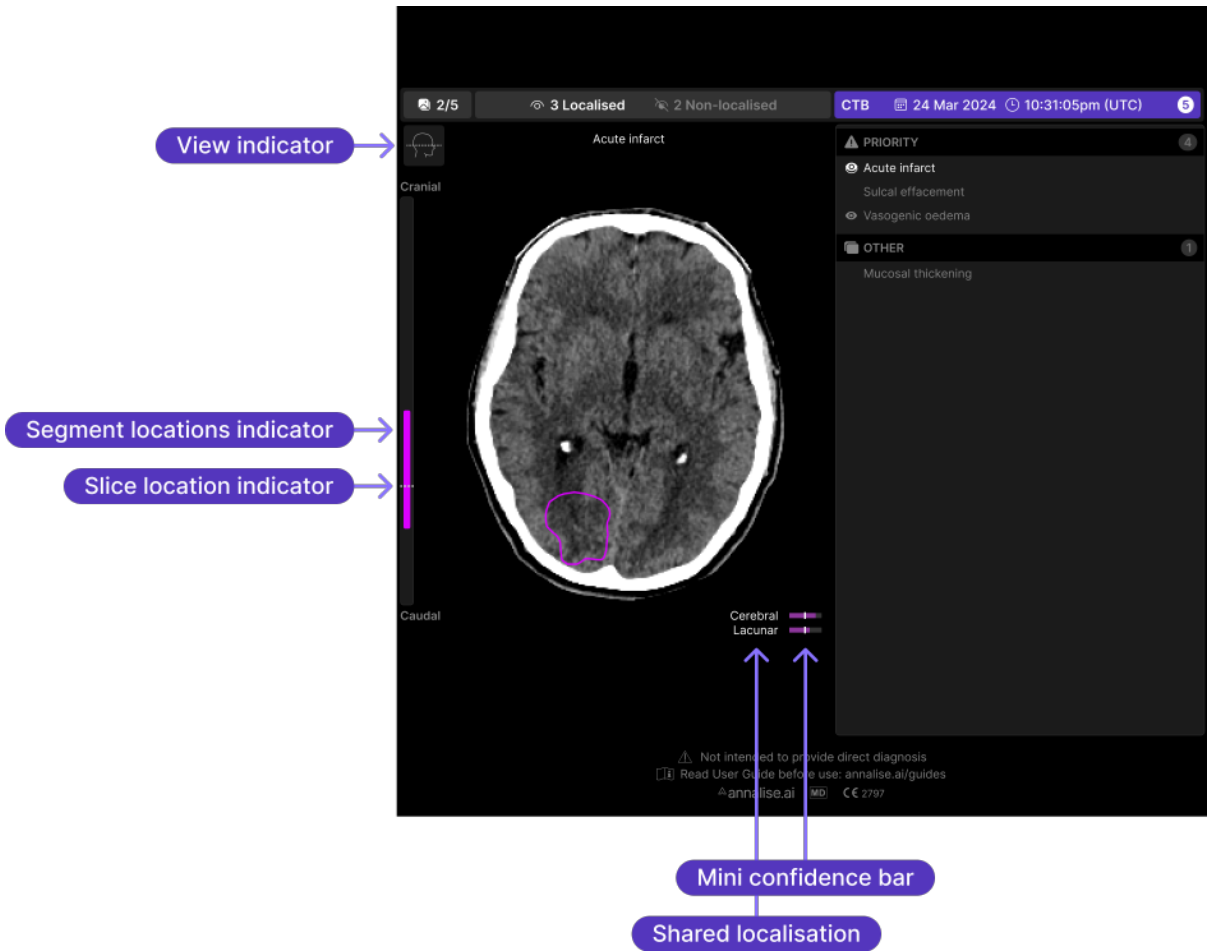
Localisation: CXR

The following example shows a CXR result with localised findings.



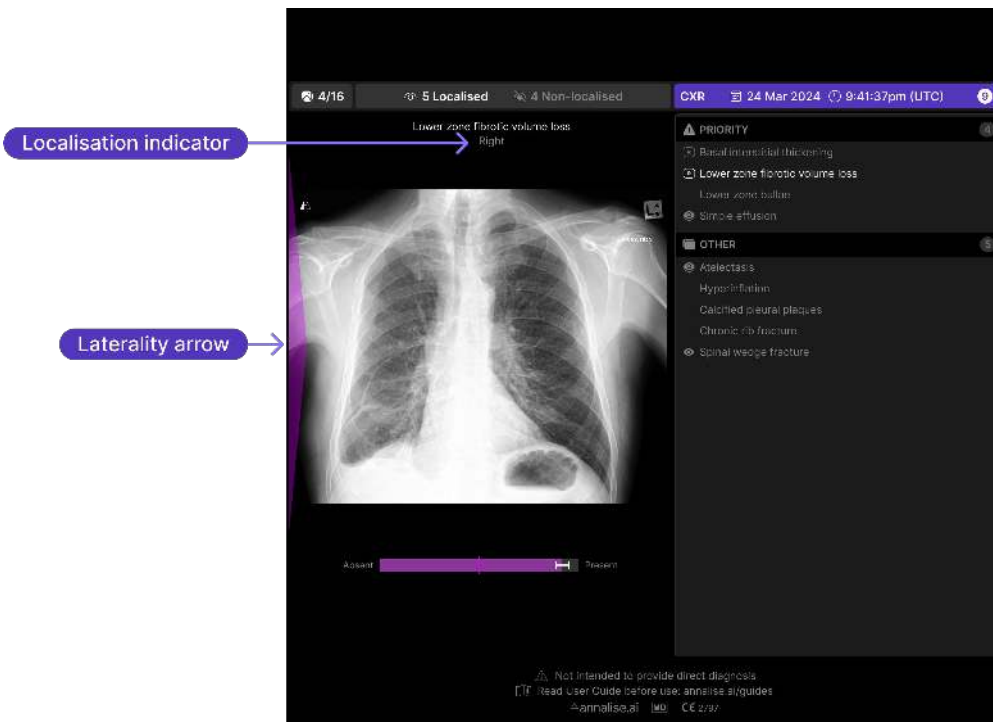
Localisation: CTB

The following example shows a CTB result with localised findings.



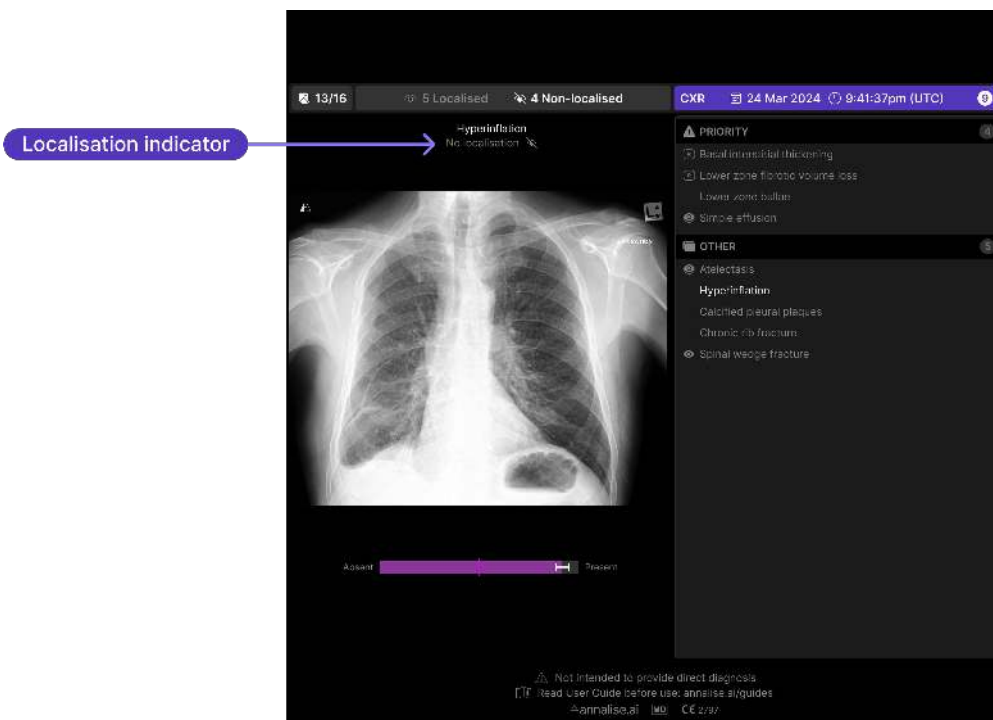
Laterality

The following example shows a CXR result with localised findings (laterality).



Non-localised findings

The following example shows a CXR result with non-localised findings.




Info bar functions




The following functions and components display on the Info bar:

Function	Details
Image counter	The Image counter indicates the position of the current image within the total number of images in the study.
Localised finding count	The total number of localised findings displayed in the result. The icon beside the finding count also displays in the Findings List to indicate that a finding is localised.
Non-localised finding count	The total number of non-localised findings displayed in the result. The icon beside the finding count also displays in the Findings List to indicate when a finding is non-localised.
Modality type	The Modality type indicates the current modality (i.e. 'CXR' or 'CTB').
AI results time stamp	The date and time that the AI results were detected displays in the middle of the Info bar.
Finding count	The Finding count indicates the total number of findings detected in the result. This includes both the number of findings that display in the Findings List and the total number of detected findings.

Summary Panel functions


The following functions and components display on the Summary Panel:

Function	Details								
Info bar	The Info bar displays at the top of the panel. See Info bar functions, page 46 .								
Product description	The product name ('Annalise Enterprise') and product description.								
Disclaimers	<p>'First available AI result'</p> <p>If multiple predictions are triggered (for example, if additional images in the study were routed to Annalise Secondary Capture a few minutes after the first images were sent), only the first successfully completed AI result will display.</p> <p>See:</p> <ul style="list-style-type: none"> • Processed images, below • Not all images in the study are present in the Secondary Capture result, page 85 <p>'For trained clinicians only. Not for patient interpretation'</p> <p>See Intended user, page 4.</p>								
Finding instructions	<p>The Finding instructions outline the available outcomes that can display while you are viewing images in the result.</p> <p>Each image will display one of these outcomes (depending on the findings detected). These include:</p> <table border="1"> <tbody> <tr> <td>Localised findings</td> <td>Key regions of interest are indicated</td> </tr> <tr> <td>Laterality findings</td> <td>Relevant sides of the body are indicated</td> </tr> <tr> <td>Non-localised findings</td> <td>Findings may not have any region of interest</td> </tr> <tr> <td>Single slice displayed per finding (CTB only)</td> <td>Use original series to review extent of each finding.</td> </tr> </tbody> </table> <p> These instructions do not display if there are no findings detected.</p>	Localised findings	Key regions of interest are indicated	Laterality findings	Relevant sides of the body are indicated	Non-localised findings	Findings may not have any region of interest	Single slice displayed per finding (CTB only)	Use original series to review extent of each finding.
Localised findings	Key regions of interest are indicated								
Laterality findings	Relevant sides of the body are indicated								
Non-localised findings	Findings may not have any region of interest								
Single slice displayed per finding (CTB only)	Use original series to review extent of each finding.								
Processed images (CXR only)	The images that have been analysed in the study to produce the AI findings.								
Processed series (CTB only)	The number and description of the series analysed in the study to produce the AI findings.								










Function	Details
Scroll instructions	<p>Depending on the options available on your PACS, you can use any of the following actions to scroll through the results:</p> <ul style="list-style-type: none">• click and drag• use the wheel on your mouse• use the arrow keys on your keyboard <p> These instructions do not display if there are no findings detected.</p>
Labelling details	<p>Labelling details include:</p> <ul style="list-style-type: none">• product warning• instructions about reading the <i>Annalise Enterprise User Guide</i> before using the product• Annalise.ai trademark• Medical Device and CE labelling symbols <p> To check other labelling details (such as software version, UDI and manufacturer name and address), check the DICOM metadata in your PACS viewer.</p>
Findings List	<p>The Findings List includes all findings detected by the AI algorithm for the current result.</p> <p>You can access further details about these findings as you scroll through the list. See Findings, page 51.</p> <p>There are a maximum number of findings that can display. If the number of findings detected by the AI algorithm exceeds this number:</p> <ul style="list-style-type: none">• the highest priority findings will display first• the additional findings detected (but not shown) will have a lower priority than those that display• the number of additional findings detected (but not shown) will be indicated at the bottom of the Findings List <p> If no findings are detected, the 'No AI findings detected' message displays.</p>

Finding Panel functions

The following functions and components display on the Finding Panel:

Function	Details
Info bar	See Info bar functions, page 46 .
Finding name	The Finding name displays the name of the current finding in the Findings List.
Localisation indicator	Indicates whether localisation is available for the current finding. Options that can display include: <ul style="list-style-type: none"> • Right – indicates right laterality • Left – indicates left laterality • Bilateral – indicates both left and right laterality • No localisation • [Blank] – indicates that localisation is available • [Additional characterisation of the finding] – may display where applicable (<i>CTB only</i>)
View indicator (<i>CTB only</i>)	Indicates the active view of the source image. Options include: <ul style="list-style-type: none"> • Axial • Sagittal • Coronal
Segment locations indicator (<i>CTB only</i>)	Indicates the relative segment locations for the current finding within the sequence of images (for the applicable view).
Slice location indicator (<i>CTB only</i>)	Indicates the relative slice location of the current image within the sequence of images (for the applicable view).
Source image	The image analysed in the study that is relevant to the current finding. <div style="border: 1px solid #ccc; border-radius: 10px; padding: 10px; background-color: #f0f0f0;">  For CXR, each finding may display one or more source images as you scroll through the list. </div>
Localisation	If localisation is associated with the current finding: <ul style="list-style-type: none"> • the Localisation icon will display beside the finding name, and • a region of interest outline will display over the relevant area in the image.
Laterality	If laterality is associated with the current finding, the Laterality icon will display beside the finding name. The icon indicates the side (or sides) of the body to which the finding relates: <ul style="list-style-type: none"> • L – Left • R – Right • L + R – Bilateral <p>A purple Laterality arrow will also indicate laterality on the left, right (or bilateral) sides of the image.</p>

Function	Details
Confidence bar	<p>The Confidence bar provides a visual indication of the confidence of the AI model that a particular finding is present.</p> <p>It enables you to see the relationship between the Confidence threshold, the Confidence score and the 95% Confidence interval.</p>
Confidence score	<p>The purple area in the confidence bar shows the AI model's Confidence score.</p> <p>This score indicates the model's confidence that a finding is present.</p>
Confidence threshold	<p>The Confidence threshold (i.e. the operating point) is a fixed threshold that is compared with the AI model's Confidence score.</p> <p>A confidence score above the confidence threshold will result in the AI model determining that the finding is present.</p>
Confidence interval	<p>The 95% Confidence interval shows the AI model's degree of certainty about its Confidence score.</p> <p>The smaller the distance between the confidence interval endpoints, the higher the score certainty.</p>
Mini confidence bar (CTB only)	<p>The Mini confidence bar displays a smaller version of the confidence bar (but shows the confidence score and confidence threshold only).</p> <p>See Confidence bar, above.</p> <p>It displays next to the findings that are associated with a shared localisation only.</p>
Shared localisation (CTB only)	<p>The Shared localisation icon displays when more than one finding shares the same localisation.</p> <p>These findings are grouped together to make it easier for the clinician to interpret the study. Each group includes a shared localisation 'title' (the finding name) and the associated findings displayed underneath (each with their own confidence levels – see Mini confidence bar, above).</p>
Labelling details	<p>See Labelling details, page 48.</p>
Finding groups	<p>Finding groups are located on the Findings List.</p> <p>All findings are grouped according to status or type. Each finding has both a pre-defined display order and a group to which it belongs.</p> <p>The following default groups display:</p> <ul style="list-style-type: none"> • Priority • Other • Technical (<i>displays if one or more findings are classified as 'technical', i.e. non-anatomical artefacts which occurred during the X-ray or scan</i>). <p>Your organisation can request to configure the following:</p> <ul style="list-style-type: none"> • group names • displaying certain findings only • adding another group, and/or • determining the findings that display within each group.
Group count	<p>The Group count that displays beside each finding group indicates the number of findings in that group.</p>

Function	Details						
Findings	<p>The suspected radiological findings detected by the AI model display in the Findings List.</p> <p>The name of the current finding will be highlighted as you scroll through the list.</p> <p>If the model detects that there aren't any findings for the study, the 'No findings detected' message will display.</p>						
Finding icons	<p>The following icons display in the Findings List when localisation or laterality is associated with the finding.</p> <table border="1" data-bbox="469 602 1283 1012"> <tbody> <tr> <td data-bbox="469 602 671 663">Localisation</td> <td data-bbox="671 602 1283 663">  Localisation is associated with the finding. </td> </tr> <tr> <td data-bbox="469 663 671 781">Multiple localisations</td> <td data-bbox="671 663 1283 781">  <p><u>CXR</u>: Localisation is available on multiple views.</p> <p><u>CTB</u>: Multiple findings have the same localisation (see Shared localisation, page 50).</p> </td> </tr> <tr> <td data-bbox="469 781 671 1012">Laterality</td> <td data-bbox="671 781 1283 1012">  Indicates the side (or sides) of the body to which the finding relates: <ul style="list-style-type: none"> • L - Left • R - Right • L + R - Bilateral <p>See Laterality, page 49.</p> </td> </tr> </tbody> </table>	Localisation	 Localisation is associated with the finding.	Multiple localisations	 <p><u>CXR</u>: Localisation is available on multiple views.</p> <p><u>CTB</u>: Multiple findings have the same localisation (see Shared localisation, page 50).</p>	Laterality	 Indicates the side (or sides) of the body to which the finding relates: <ul style="list-style-type: none"> • L - Left • R - Right • L + R - Bilateral <p>See Laterality, page 49.</p>
Localisation	 Localisation is associated with the finding.						
Multiple localisations	 <p><u>CXR</u>: Localisation is available on multiple views.</p> <p><u>CTB</u>: Multiple findings have the same localisation (see Shared localisation, page 50).</p>						
Laterality	 Indicates the side (or sides) of the body to which the finding relates: <ul style="list-style-type: none"> • L - Left • R - Right • L + R - Bilateral <p>See Laterality, page 49.</p>						

Getting started: Annalise Secondary Capture

Overview

This section shows you how to:

- access Annalise Secondary Capture, and
- view the results.

Access Annalise Secondary Capture

Annalise Secondary Capture results are inserted into your PACS and display alongside the patient's source images.

1. Go to your PACS and open the patient study.

The Annalise Secondary Capture results will automatically display as an additional series within the patient study.

View the results

1. Select the Annalise Secondary Capture series and scroll through the results to view the AI model findings.

More than one image may display per finding.

See:

- [Finding Panel, page 43](#)
 - [Finding Panel functions, page 49](#)
 - [Scroll instructions, page 48](#)
2. Go to [Using Annalise Secondary Capture, page 53](#).

Using Annalise Secondary Capture

Overview

Annalise Secondary Capture displays the suspected radiological findings for a study in the Findings List (the results that display depend on the configuration set by your organisation).

This section shows you how to:

- review the AI findings
- interpret the confidence level of each finding

Review AI findings

Multiple findings with varying degrees of confidence may display. In these instances, it is important to use your clinical judgement when reviewing all findings.

1. Use the following functions to help you review the findings:

Function	Details
Show images analysed for the current study (CXR only)	The Summary Panel displays the images analysed for the current study (and their associated view). See: <ul style="list-style-type: none"> • Summary Panel, page 40 • Summary Panel functions, page 47
Show the series analysed for the current study (CTB only)	The Summary Panel displays the series analysed for the current study. See: <ul style="list-style-type: none"> • Summary Panel, page 40 • Summary Panel functions, page 47
Identify the number of findings present	A number displays in the following locations to indicate the number of findings identified by the AI model: <ul style="list-style-type: none"> • Finding count on the Info bar (total number of findings) • Group count next to each finding group (total for that group)

Function	Details		
Review regions of interest (ROI)	<p>If present, regions of interest will be highlighted on the image.</p>		
	<table border="1"> <tr> <td data-bbox="502 349 703 568">View localisation</td> <td data-bbox="708 349 1297 568"> <p>If localisation is associated with a finding, the Localisation icon will display next to the finding name and a region of interest outline will display on the image.</p> <p>See:</p> <ul style="list-style-type: none"> • Localisation, page 49 • Finding icons, page 51 </td> </tr> </table>	View localisation	<p>If localisation is associated with a finding, the Localisation icon will display next to the finding name and a region of interest outline will display on the image.</p> <p>See:</p> <ul style="list-style-type: none"> • Localisation, page 49 • Finding icons, page 51
	View localisation	<p>If localisation is associated with a finding, the Localisation icon will display next to the finding name and a region of interest outline will display on the image.</p> <p>See:</p> <ul style="list-style-type: none"> • Localisation, page 49 • Finding icons, page 51 	
View laterality	<p>If laterality is associated with a finding, the Laterality icon will display next to the finding name and a purple arrow (or arrows) will display on the image.</p> <p>See:</p> <ul style="list-style-type: none"> • Laterality, page 49 • Finding icons, page 51 		
Localisation does not display	<p>If localisation is not associated with a finding, the image will not be highlighted and no icon will display in the Findings List.</p> <p>To check which findings display localisation, see the Findings List, page 88.</p>		
Check view and location of slices and segments (CTB only)	<p>Check the applicable view, slice location and segment locations for the current finding in the source image.</p> <p>Only a single view, slice and window combination are shown for each finding. Review the original series in your PACS to review the extent of the finding in the brain.</p> <p>The View Indicator, Slice location indicator and Segment locations indicator are intended as a guide to the view and approximate location/s of the finding.</p> <p>See:</p> <ul style="list-style-type: none"> • View indicator, page 49 • Slice location indicator, page 49 • Segment locations indicator, page 49 		

Interpret the confidence level

A default confidence threshold for each finding will be provided for your organisation. For a finding to be considered present in the study, it must therefore have a score greater than this threshold.

For each finding, the AI model provides:



- a confidence score, and
- a 95% confidence interval.

This information is displayed on the Confidence bar in the Finding Panel.

See:

- [Confidence bar, page 50](#)
- [Confidence score, page 50](#)
- [Confidence threshold, page 50](#)
- [Confidence interval, page 50](#)

Refer to the following examples:

Confidence level	Interpretation
Higher confidence	<ul style="list-style-type: none"> • The confidence score is above the confidence threshold • Both confidence interval endpoints are above the confidence threshold • The AI model has a high confidence that the finding is present in the study 
Lower confidence	<ul style="list-style-type: none"> • The confidence score is above the confidence threshold • The lower endpoint of the confidence interval is below the confidence threshold • The AI model may have some uncertainty that the finding is present in the study 

Annalise Web Viewer

About Annalise Web Viewer

Overview

Annalise Web Viewer is an accessory intended to interface with Annalise Enterprise. It contains a Results List and Study Viewer.

The Results List displays adult chest X-ray studies and non-contrast CT brain studies analysed by the Annalise Backend. It can be configured to display the priority of the studies processed by Annalise Enterprise.

The Study Viewer displays the AI results of these studies, including suspected findings and localisation information.

Annalise Web Viewer can be accessed via an internet browser.



Annalise Web Viewer is not available in all regions (including the EU).

Annalise Web Viewer functions

Overview

The following section outlines the functions available on the Annalise Web Viewer for both CXR and CTB studies.

Main components

The Annalise Web Viewer includes the Results List and the Study Viewer (which contains the Image Panel and Findings List).

Results List

Components and functions of the Results List are shown below.

See [Results List functions](#), page 63.

The screenshot displays the Results List interface with the following callouts and functions:

- Filter options:** Located at the top, pointing to the search and filter controls.
- Triage status of AI findings:** Located at the top, pointing to the 'AL FINDINGS' column header.
- Patient search:** Located on the left, pointing to the search input field.
- Date of study:** Located on the left, pointing to the 'DATE OF STUDY' column header.
- Column choice:** Located on the left, pointing to the column selection icons.
- Results per page:** Located at the bottom, pointing to the '10', '15', '30', '50' options.
- Page navigation:** Located at the bottom, pointing to the 'Prev', '1', '2', '3', '4', '5', 'Next' controls.
- Filter by viewed status:** Located at the bottom, pointing to the 'Show All Not viewed' controls.

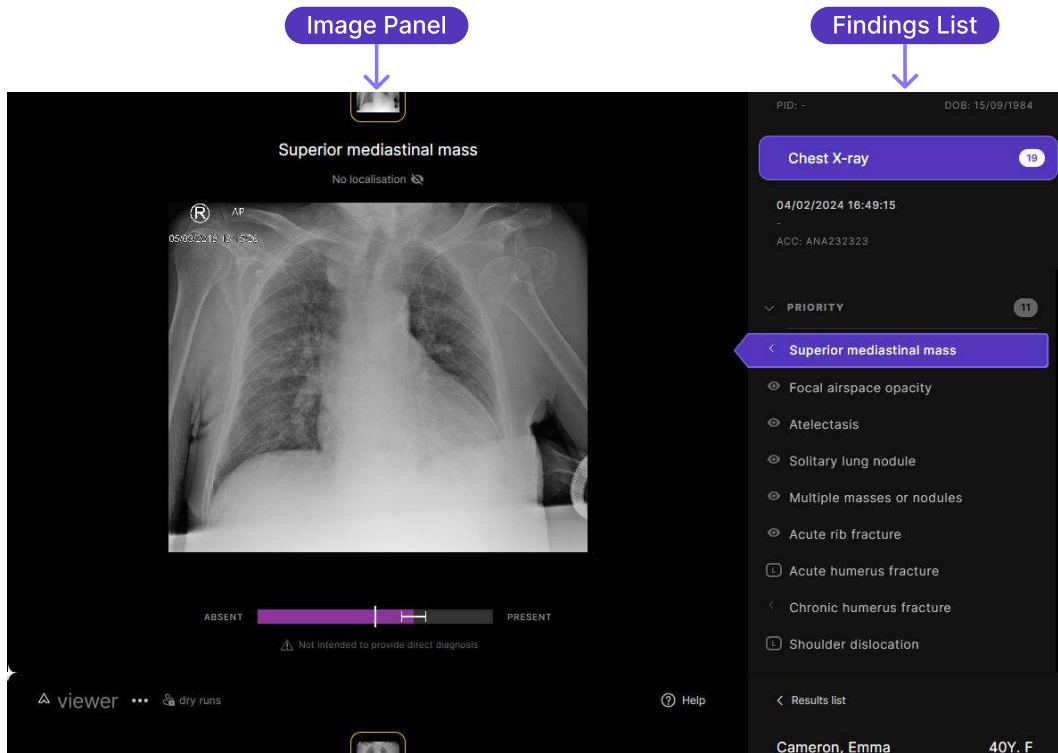
DATE OF STUDY ↓	PATIENT ID	NAME	AGE, SEX	HOSPITAL	DEPT.	SCAN	AL FINDINGS ↓
00:43 8/05/2023	D147...	JACKSON, Summer	53Y.M	GEH	SURG	CTB	
00:43 8/05/2023	Z073...	TYLOR, Christopher	64Y.M	GEH	AANDE	CTB	CRITICAL (1)
00:43 8/05/2023	Z072...	JACKSON, Jett	35Y.M	GEH	SURG	CTB	PRIORITY (1)
00:43 8/05/2023	Zw77...	TYLOR, Rider	23Y.M	GEH	AANDE	CTB	ERROR
00:43 8/05/2023	A675...	THAN, Kelly	26Y.M	GEH	AANDE	CTB	-
00:43 8/05/2023	Za87...	BUSH, Minni	27Y.M	GEH	SURG	CTB	NON-URGENT
00:43 8/05/2023	Zh34...	BUSH, Micky	42Y.M	GEH	AANDE	CTB	CRITICAL (1)
00:43 8/05/2023	B123...	BUSH, Minni	43Y.M	GEH	SURG	CTB	CRITICAL (1)
00:43 8/05/2023	A928...	BUSH, Minni	33Y.M	GEH	SURG	CTB	CRITICAL (1)
00:43 8/05/2023	A928...	BUSH, Minni	33Y.M	GEH	SURG	CTB	CRITICAL (1)

Not for diagnosis. Only showing studies processed by Annalise Enterprise.

Study Viewer

The Study Viewer displays when you select a study in the Results List.

The main components of the Study Viewer are shown below.



For further details see:

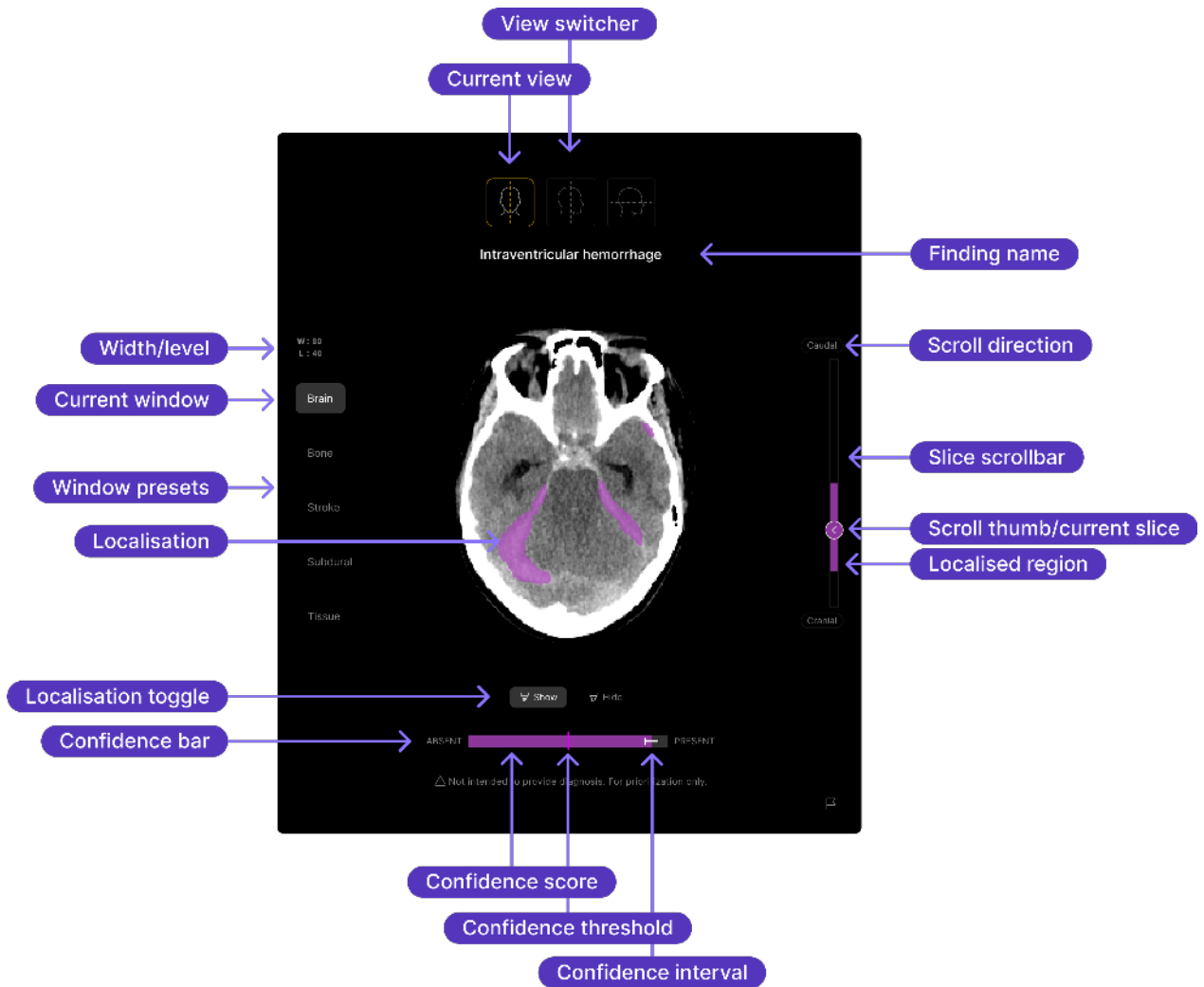
- [Study Viewer: Image Panel \(CTB\)](#), page 60
- [Study Viewer: Image Panel \(CXR\)](#), page 61
- [Study Viewer: Findings List](#), page 62
- [Study Viewer functions](#), page 65

Study Viewer: Image Panel (CTB)

Components and functions of the Image Panel in the Study Viewer (for CTB studies) are shown below.

Depending on the study's findings, the study may display localisation or laterality. The study in this example includes localisation.

See [Study Viewer: Image Panel](#), page 65.

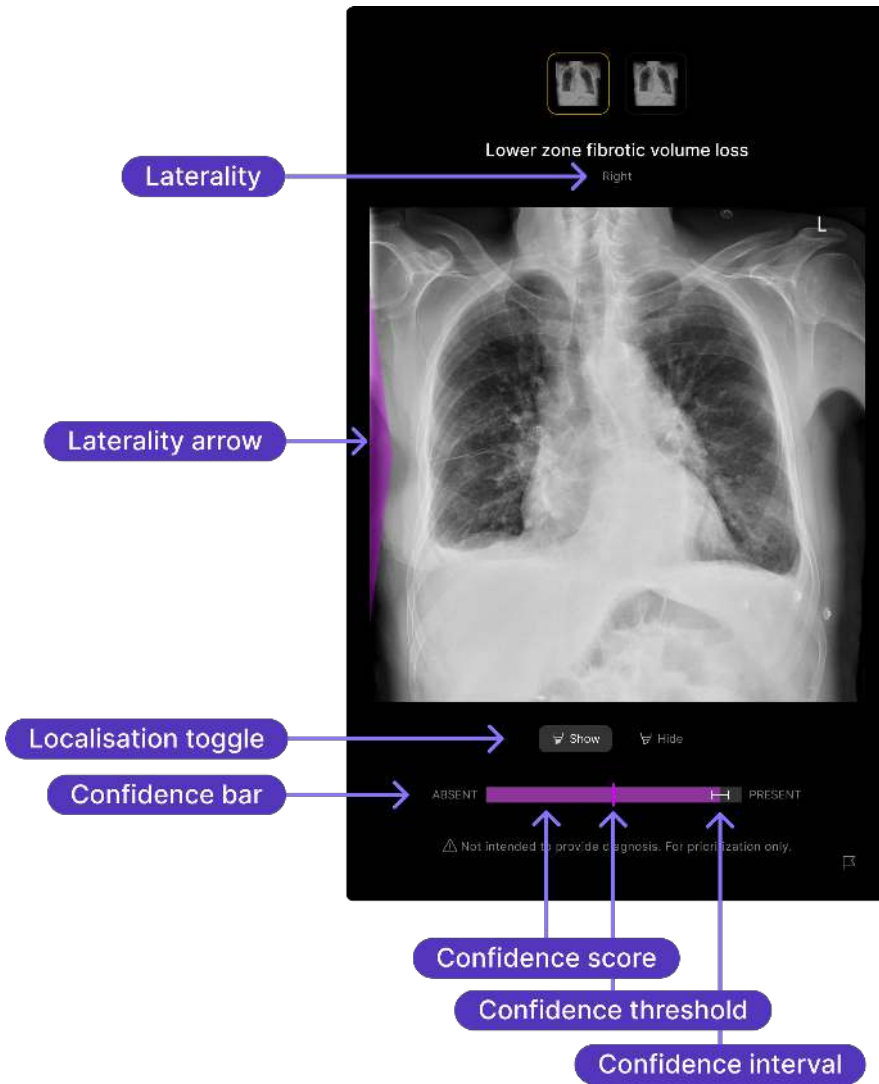


Study Viewer: Image Panel (CXR)

Components and functions of the Image Panel in the Study Viewer (for CXR studies) are shown below.

Depending on the study's findings, the study may display localisation or laterality. The study in this example includes laterality.

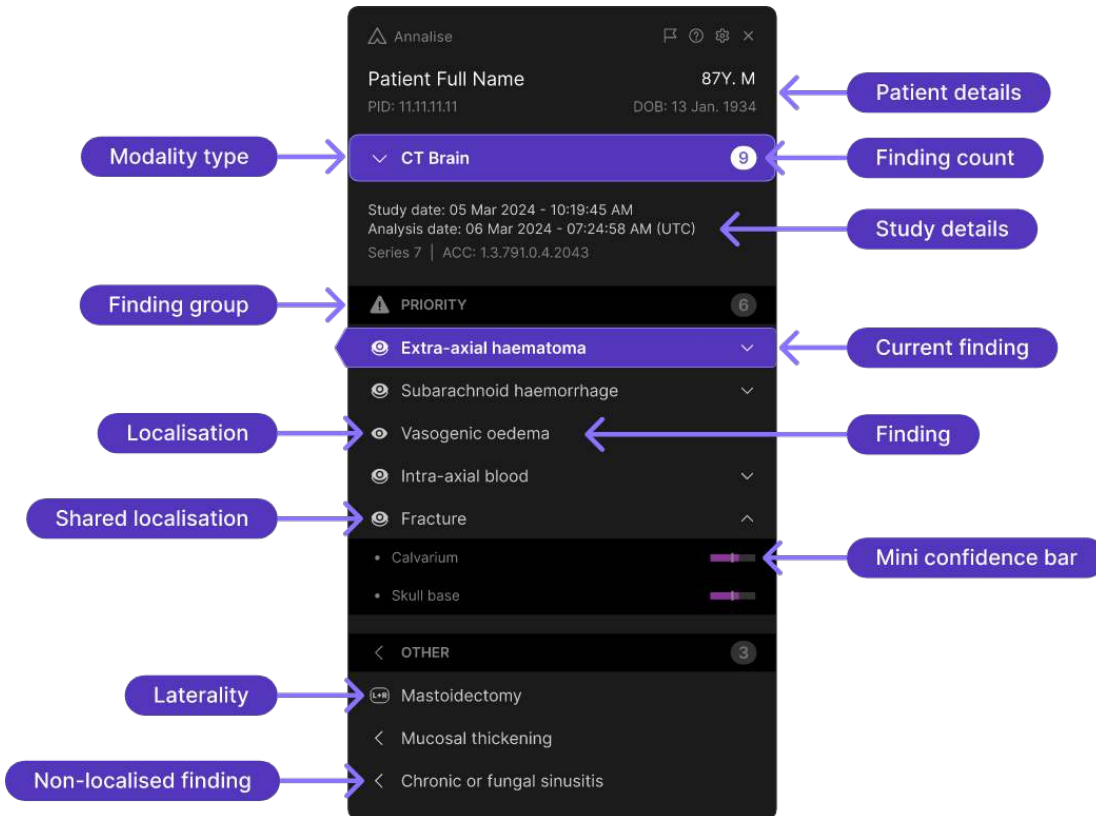
See [Study Viewer: Image Panel](#), page 65.



Study Viewer: Findings List

Components and functions of the Findings List in the Study Viewer are shown below.

See [Study Viewer: Findings List, page 67](#).



Results List functions

The Results List displays the studies analysed by the Annalise Backend.

You can sort these studies by date of study, analysed date or by the criticality of the AI findings, or use the search and filter functions at the top of the page to find specific studies.

Results List fields

The following fields are available for each study.




The default view of the Results List does not display all columns listed below. To show or hide columns, see [Show or hide columns, page 71](#).

Function	Details
Date of study	<p>The date and time the X-ray/CT machine recorded the study.</p> <p> This is the 'Study Date' in the DICOM.</p>
Date analysed	<p>The date and time the study was processed by the AI model.</p> <p><i>Does not display in the default view.</i></p>
Patient ID	<p>The patient's ID.</p> <p> Only the first four numbers of the patient ID display. Hover your mouse over these numbers to see the full ID.</p>
Name	The patient's name.
Age/Sex	The patient's age and sex.
DoB	<p>The patient's date of birth.</p> <p><i>Does not display in the default view.</i></p>
ACC	<p>The unique accession number given to each study.</p> <p><i>Does not display in the default view.</i></p>
Scan	The imaging modality or scan type (i.e. CXR or CTB).
Hospital	The hospital at which the study was performed.
Dept.	<p>The internal department that requested the study.</p> <p> This is the 'Requesting Service' in the DICOM.</p>

Function	Details
AI findings	<p>The triage status of the findings identified by the AI model.</p> <p>Studies without detected findings are marked with a dash ('-').</p> <p>If an error occurs during the processing of a study, the word 'Error' will display. If this happens, click the study to display the reason for the error.</p> <p>Your organisation can request to configure the following details:</p> <ul style="list-style-type: none"> • priority group names • priority group order • adding another priority group (there are three default groups), and/or • determining the findings allocated to each group.

Results List functions

The following functions are available on the Results List.

Function	Details
Patient search	<p>Search for a patient by patient ID, patient name or accession number.</p> <p>See Search for a patient, page 71.</p>
Filters	<p>Filter search results by hospital, department, scan and/or date or date range.</p> <p>See Filter studies, page 71.</p>
Sort	<p>Sort studies by date of study or by criticality of the AI finding.</p> <p>See Sort studies, page 71.</p>
Viewed status	<p>See which studies have been viewed.</p> <p> The Viewed status icon displays to the right of the study when it has been opened and viewed.</p> <p>You can also filter studies by viewed status.</p> <p>See Filter studies, page 73.</p>
Delete	<p>If you want to delete a study (due to incorrect details or an upload error), contact your internal IT support team.</p>
Column choice	<p>Hide or display columns in the Results List.</p> <p>See Show or hide columns, page 71.</p>
Results per page	<p>Select the number of results to display per page.</p> <p>See Select number of results per page, page 71.</p>
Page navigation	<p>Use the pagination controls at the bottom of the screen to navigate through the results pages.</p> <p>See Navigate results, page 71.</p>

Study Viewer functions


The Study Viewer opens when you select a study in the Results List. The Study Viewer contains the Image Panel and the Findings List.

Study Viewer: Image Panel

The Image Panel in the Study Viewer displays the current image associated with the selected finding, including any localisation or laterality related to the finding (and its confidence level). It also enables you to access different views of the study.

The following functions display on the Image Panel in the Study Viewer:

Function	Details				
View switcher	<p>The View switcher icons enable you to switch between image views.</p> <p>The following views are available:</p> <table border="1"> <tbody> <tr> <td>CXR</td> <td> <ul style="list-style-type: none"> • Frontal • Lateral (may not be present if not processed) </td> </tr> <tr> <td>CTB</td> <td> <ul style="list-style-type: none"> • Axial • Sagittal • Coronal </td> </tr> </tbody> </table> <p>The active view is highlighted.</p>	CXR	<ul style="list-style-type: none"> • Frontal • Lateral (may not be present if not processed) 	CTB	<ul style="list-style-type: none"> • Axial • Sagittal • Coronal
CXR	<ul style="list-style-type: none"> • Frontal • Lateral (may not be present if not processed) 				
CTB	<ul style="list-style-type: none"> • Axial • Sagittal • Coronal 				
Finding name	The Finding name displays the name of the finding selected in the Findings List.				
Width/level (CTB only)	<p>The Width/level indicates the predetermined width and level of the selected greyscale spectrum:</p> <ul style="list-style-type: none"> • W – indicates window width • L – indicates window level 				
Window presets (CTB only)	<p>Window presets enable you to view the following pre-configured options (for CTB studies):</p> <ul style="list-style-type: none"> • Brain • Bone • Stroke • Subdural • Tissue <p>When you select an option, the associated width/level values display (see Width/level, above).</p> <p>The active window is highlighted.</p>				
Slice scrollbar (CTB only)	<p>The Slice scrollbar enables you to scroll through all available slices for the current CTB study (see Scroll thumb/Current slice, below).</p> <p>If localisation is associated with the finding, the purple areas in the scrollbar indicate the areas of localisation in the study.</p>				
Scroll thumb/Current slice (CTB only)	<p>The Scroll thumb/Current slice enables you to scroll through the images.</p> <p>It also indicates the current slice position in the Slice scrollbar.</p>				

Function	Details
Scroll direction (CTB only)	<p>The Scroll direction displays at both ends of the Slice scrollbar.</p> <p>These indicators show the direction you are moving in as you scroll through the images.</p>
Localisation	<p>If localisation is associated with the finding, it will display as a purple overlay over the relevant area in the image.</p>
Laterality	<p>If localisation cannot be localised to a specific area, a purple Laterality arrow will indicate laterality on the left, right (or bilateral) sides of the image.</p>
Localisation toggle	<p>The Localisation toggle enables you to show or hide localisation for the current study.</p> <div style="border: 1px solid #ccc; border-radius: 10px; padding: 10px; background-color: #f0f0f0; margin-top: 10px;"> <p> If you switch this option off, it will automatically switch on again as soon as you hover over either a Localisation or Laterality icon.</p> </div>
Confidence bar	<p>The Confidence bar provides a visual indication of the confidence of the AI model that a particular finding is present.</p> <p>It enables you to see the relationship between the Confidence threshold, the Confidence score and the 95% Confidence interval.</p>
Confidence score	<p>The purple area in the confidence bar shows the AI model's Confidence score.</p> <p>This score indicates the model's confidence that a finding is present.</p>
Confidence threshold	<p>The Confidence threshold (i.e. the operating point) is a fixed threshold that is compared with the AI model's Confidence score.</p> <p>A confidence score above the confidence threshold will result in the AI model determining that the finding is present.</p>
Confidence interval	<p>The 95% Confidence interval shows the AI model's degree of certainty about its Confidence score.</p> <p>The smaller the distance between the confidence interval endpoints, the higher the score certainty.</p>


Study Viewer: Findings List

The Findings List in the Study Viewer displays details about the patient and the modality as well as information about the current study and its associated findings.

By default, the findings display in order of clinical severity (as determined by Annalise.ai expert radiologists), but you can configure this order to meet your requirements.

The following functions display on the Findings List:

Function	Details								
Patient details	<p>The following patient details display for the current study:</p> <ul style="list-style-type: none"> • Name • Age • Gender • Patient ID • Date of birth (DOB) 								
Modality type	<p>The Modality type indicates the current modality (i.e. 'Chest X-ray' or 'CT Brain').</p> <p>It also displays the total number of findings for the current study.</p>								
Study details	<p>The Study details display the following:</p> <table border="1"> <tbody> <tr> <td>Study date and time</td> <td>The date and time the X-ray/CT machine recorded the study.</td> </tr> <tr> <td>Analysis date and time</td> <td>The date and time the AI model processed the study.</td> </tr> <tr> <td>Study description</td> <td> <p>CTB: The series number within the current study and the series description.</p> <p>CXR: The number of other analysed images for the study.</p> <p>If the description is more than 64 characters, an ellipsis (...) will display at the end, indicating that there is further information in this field. If this occurs, hover your mouse over the ellipsis to see the full description.</p> </td> </tr> <tr> <td>Accession number</td> <td>A unique number used to identify a diagnostic report. All images within a study will have the same accession number.</td> </tr> </tbody> </table>	Study date and time	The date and time the X-ray/CT machine recorded the study.	Analysis date and time	The date and time the AI model processed the study.	Study description	<p>CTB: The series number within the current study and the series description.</p> <p>CXR: The number of other analysed images for the study.</p> <p>If the description is more than 64 characters, an ellipsis (...) will display at the end, indicating that there is further information in this field. If this occurs, hover your mouse over the ellipsis to see the full description.</p>	Accession number	A unique number used to identify a diagnostic report. All images within a study will have the same accession number.
Study date and time	The date and time the X-ray/CT machine recorded the study.								
Analysis date and time	The date and time the AI model processed the study.								
Study description	<p>CTB: The series number within the current study and the series description.</p> <p>CXR: The number of other analysed images for the study.</p> <p>If the description is more than 64 characters, an ellipsis (...) will display at the end, indicating that there is further information in this field. If this occurs, hover your mouse over the ellipsis to see the full description.</p>								
Accession number	A unique number used to identify a diagnostic report. All images within a study will have the same accession number.								
Findings	<p>The suspected radiological findings detected by the AI model.</p> <p>If you hover over a finding in the Findings List:</p> <ul style="list-style-type: none"> • it will be highlighted purple in the Findings List, and • this finding will display on the Image Panel. <p>If the model detects that no findings are present, the Annalise Web Viewer will not contain any results (and the 'No AI findings detected' message will display).</p>								
Finding count	<p>The Finding count that displays beside each finding group indicates the number of findings in that group.</p>								

Function	Details								
Finding groups	<p>Finding groups are located on the Findings List.</p> <p>All findings are grouped according to status or type. Each finding has both a pre-defined display order and a group to which it belongs.</p> <p>The following default groups display:</p> <table border="1"> <tr> <td><i>Priority</i></td> <td>Findings in this group always display</td> </tr> <tr> <td><i>Other</i></td> <td></td> </tr> <tr> <td><i>User added</i></td> <td>This group displays if a user adds any additional findings</td> </tr> <tr> <td><i>Technical</i></td> <td>This group displays if one or more findings are classified as 'technical' (i.e. non-anatomical artefacts which occurred during the X-ray or scan)</td> </tr> </table> <p>Your organisation can request to configure the following:</p> <ul style="list-style-type: none"> • group names • displaying certain findings only • adding another group, and/or • determining the findings that display within each group. <div style="border: 1px solid #ccc; background-color: #f0f0f0; padding: 5px; margin-top: 10px;"> <p> As the first group will always contain findings that are more clinically relevant (regardless of whether it is called 'Priority' or has another name), it cannot be collapsed.</p> </div>	<i>Priority</i>	Findings in this group always display	<i>Other</i>		<i>User added</i>	This group displays if a user adds any additional findings	<i>Technical</i>	This group displays if one or more findings are classified as 'technical' (i.e. non-anatomical artefacts which occurred during the X-ray or scan)
<i>Priority</i>	Findings in this group always display								
<i>Other</i>									
<i>User added</i>	This group displays if a user adds any additional findings								
<i>Technical</i>	This group displays if one or more findings are classified as 'technical' (i.e. non-anatomical artefacts which occurred during the X-ray or scan)								
Localisation	<p>The Localisation icon displays when localisation is associated with the finding.</p> <p>See Localisation, page 66.</p>								
Shared localisation (CTB only)	<p>The Shared localisation icon displays when more than one finding shares the same localisation.</p> <p>These findings are grouped together to make it easier for the clinician to interpret the study. Each group includes a shared localisation 'title' (the finding name) and the associated findings displayed underneath (each with their own confidence levels - see Mini confidence bar), below.</p> <p>When you click this title, the shared localisation displays on the Image Panel.</p> <p>By default, each shared localisation group will be collapsed. Click the down arrow next to the title to display the associated findings or click the up arrow to collapse them.</p>								
Mini confidence bar (CTB only)	<p>The Mini confidence bar displays a smaller version of the confidence bar (but shows the confidence score and confidence threshold only).</p> <p>See Confidence bar, page 66.</p> <p>It displays next to the findings that are associated with a shared localisation only.</p>								

Function	Details
Laterality	<p>The Laterality icon displays if the finding is localised to left or right.</p> <p>The icon indicates the side (or sides) of the body to which the finding relates:</p> <ul style="list-style-type: none">• L - Left• R - Right• L+R - Bilateral <p>See Laterality, page 66.</p>

Getting started: Annalise Web Viewer

Overview

This section shows you how to:

- launch Annalise Web Viewer
- access studies in the Results List
- filter studies
- sort studies, and
- view the results.

Launch Annalise Web Viewer

Follow these steps to launch the Annalise Web Viewer.

1. Go to the Annalise Web Viewer URL provided by your organisation.
2. Enter your username and password, then click **Sign in**.

Use the same username and password you use to log into Windows.



You will only need to re-enter your credentials when reminded by your security policy, or if you log into another machine.

Access studies in the Results List

You don't need to refresh your browser to view new studies in the Results List. Studies processed by Annalise.ai will display automatically, with the most recent studies at the top of the list.

The default view displays studies from all hospitals and departments that have been processed at any time.



While a study is being processed, a 'processing' message will display in the **AI Findings** column. Although the study can't be accessed during this time, the results will display as soon as the study has been processed.

Refer to the following table to help you:

- search for a patient
- filter and/or sort studies
- navigate through the Results List
- show or hide columns and/or select the number of results you want to display per page
- log out of Annalise Web Viewer

Function	Details
Search for a patient	<p>To search for a patient:</p> <ol style="list-style-type: none"> 1. Go to the Search field at the top left of the Results List. 2. Type the patient's ID, name or ACC (accession number). You can use a partial match for the patient's name or ACC, but you must use an exact match to locate the patient's ID (the patient ID is not case sensitive). 3. Press the Return key or click Search. If no results are found, a '<i>No results found</i>' message will display. 4. Click Reset to return to the default view.
Filter studies	<p>You can filter studies using patient ID, name or ACC, or filter by hospital, department, scan and/or date or date range.</p> <p>You can also filter studies by viewed status.</p> <p>See Filter studies, page 73.</p>
Sort studies	<p>You can sort studies by date of study (the 'Updated date' in the DICOM), analysed date or AI finding criticality.</p> <p>See Sort studies, page 72.</p>
Navigate results	<p>Use the pagination controls at the bottom right of the screen to navigate through the results pages.</p> <p>Click either a page number or click Next to go to the next page.</p>
Show or hide columns	<p>By default, the Date of Study, Patient ID, Name, Age/Sex, Hospital, Dept. and AI Findings columns display.</p> <p>To show or hide columns:</p> <ol style="list-style-type: none"> 1. Click the column chooser ('three bar') icon at the bottom left of the screen. 2. Click to select or clear the relevant columns, or click All to display all columns.
Select number of results per page	<p>At the bottom left of the screen, click to select the number of results to display per page.</p>
Log out of Annalise Web Viewer	<p>At the top of the screen, click Sign out.</p>

Sort studies

You can sort studies by date of study (the 'Updated date' in the DICOM), analysed date or AI finding criticality.

Click the relevant column header to sort studies in either:

- ascending order (earliest/oldest studies at the top of the list), or
- descending order (most recent studies at the top of the list).


The Results List displays in descending order by default.

Sort option	Action
Date of study	<ol style="list-style-type: none">1. Click the Date of Study column header. Results will be sorted in ascending order.2. Click the column header again to sort in descending order.
Analysed date	<ol style="list-style-type: none">1. Ensure that the Date Analysed column displays in the Results List (see Show or hide columns, page 71).2. Click the Date Analysed column header. Results will be sorted in ascending order.3. Click the column header again to sort in descending order.
AI finding criticality	<ol style="list-style-type: none">1. Click the AI Findings column header. The most critical studies will display at the top of the list.2. Click the column header again to reverse the sort order.

Filter studies

Follow these steps to filter studies in the Results List.

- Using the options at the top of the page, select the relevant search parameters (then click **Search**):

Filter option	Action
Patient details	Go to the Patient ID, Name or ACC field and type the relevant patient details.
Hospital	Click Any Hospital then select the relevant option. <i>Displays only if there is existing hospital data.</i>
Department	Click Any Dept. then select the relevant option. <i>Displays only if there is existing department data.</i>
Scan	Click Any scan then select the relevant option.
Date/s	Go to the Any Time dropdown and either: <ul style="list-style-type: none"> select one of the date options, or click Dates then choose the relevant 'From' and 'To' dates <div style="border: 1px solid #ccc; border-radius: 5px; padding: 5px; margin-top: 10px;">  Defaults to 'Any Time' when the system is installed. </div>

- Other filter options are available at the bottom right of the Results List:

Filter option	Action
Studies that have not yet been reviewed	Click Not viewed .
All studies	Click All .

Save filter

You can save a filter which uses hospital, department and/or date/time parameters.

Choose the relevant option/s, then click **Save filters**.

The saved filter will now be the default for the current machine.



You can either override or clear this saved filter at any time (see [Reset filter, page 74](#)).

Reset filter

If you have filtered the Results List, saved a search or overridden a saved search, you can either reset or clear these filters.

Option	Action
Reset Results List (without a saved filter)	Click Reset . The Results List will display all studies.
Reset a saved filter	If you have overridden a saved filter, click Reset . The Results List will revert to the default filter for the current machine.
Clear a saved filter	Click to select the 'Any Hospital', 'Any Dept.' and 'Any Time' options, then click Search . The Results List will display all studies.

View the results

Follow these steps to view the results of a study.

1. In the Results List, click the study that you want to review.
The study displays in the Web Viewer.
2. Go to [Using the Annalise Web Viewer, page 75](#).

Using the Annalise Web Viewer

Review AI findings

The Annalise Web Viewer displays the suspected radiological findings for a study in the Findings List (the results that display depend on the configuration set by your organisation).

This section shows you how to:


- review the findings
- interpret the confidence level of each finding

Review the findings

Multiple findings with varying degrees of confidence may display. In these instances, it is important to use your clinical judgement when reviewing all findings.

Use the following functions to help you review the findings:

Function	Details				
Show images analysed for the current study	<p>Select a finding in the Findings List to display it in the Image Panel.</p> <table border="1"> <tr> <td>CXR studies</td> <td>You can view the current image in the Image Panel</td> </tr> <tr> <td>CTB studies</td> <td> <p>Click and drag the Scroll thumb (or use your mouse wheel) to scroll through the images.</p> <p>See:</p> <ul style="list-style-type: none"> • Scroll thumb/Current slice, page 65 • Slice scrollbar, page 65 </td> </tr> </table>	CXR studies	You can view the current image in the Image Panel	CTB studies	<p>Click and drag the Scroll thumb (or use your mouse wheel) to scroll through the images.</p> <p>See:</p> <ul style="list-style-type: none"> • Scroll thumb/Current slice, page 65 • Slice scrollbar, page 65
CXR studies	You can view the current image in the Image Panel				
CTB studies	<p>Click and drag the Scroll thumb (or use your mouse wheel) to scroll through the images.</p> <p>See:</p> <ul style="list-style-type: none"> • Scroll thumb/Current slice, page 65 • Slice scrollbar, page 65 				
Switch between views	<p>On some clinical findings, the regions of interest may be highlighted on multiple views.</p> <p>To switch between views, click the View Switcher to navigate to other available views (the highlighted icon indicates the active view).</p> <p>For CTB studies, you can also use the Width/level to view the relevant pre-configured window presets.</p> <p>See:</p> <ul style="list-style-type: none"> • View switcher, page 65 • Width/level, page 65 				
Identify the number of findings present	<p>A number displays in the following locations to indicate the number of findings identified by the AI model:</p> <ul style="list-style-type: none"> • beside the Modality type (total number of findings), and • next to each findings group (total for that group). <p>Click the down arrow beside any findings with shared localisation to view all associated findings (see Shared localisation, page 68).</p>				
Switch localisation/laterality option on or off	<p>To switch the localisation/laterality option on or off, click the Localisation toggle at the bottom of the Image Panel.</p> <p>See Localisation toggle, page 66.</p>				

Function	Details						
Review regions of interest (ROI)	<p>If present, regions of interest (ROI) will be highlighted on the image displayed in the Image Panel.</p>						
	<table border="1"> <tr> <td>View localisation</td> <td> <p>If localisation is associated with a finding, a Localisation icon will display next to the finding name in the Findings List and a purple overlay will display on the image when you select the finding.</p> <p>For CTB studies, you can also use the Scroll thumb to scroll through the areas highlighted in purple on the Slice scrollbar.</p> </td> </tr> <tr> <td>View laterality</td> <td> <p>If laterality is associated with a finding, a Laterality icon will display next to the finding name in the Findings List and a purple arrow (or arrows) will display on the image when you select the finding.</p> </td> </tr> <tr> <td>Localisation does not display</td> <td> <p>If the AI model indicates that a finding is present and its location is obvious to the clinician, localisation will not display for that finding (and the Localisation icon will not show in the Findings List).</p> <p>To check which findings display localisation, see the Findings list, page 88.</p> </td> </tr> </table>	View localisation	<p>If localisation is associated with a finding, a Localisation icon will display next to the finding name in the Findings List and a purple overlay will display on the image when you select the finding.</p> <p>For CTB studies, you can also use the Scroll thumb to scroll through the areas highlighted in purple on the Slice scrollbar.</p>	View laterality	<p>If laterality is associated with a finding, a Laterality icon will display next to the finding name in the Findings List and a purple arrow (or arrows) will display on the image when you select the finding.</p>	Localisation does not display	<p>If the AI model indicates that a finding is present and its location is obvious to the clinician, localisation will not display for that finding (and the Localisation icon will not show in the Findings List).</p> <p>To check which findings display localisation, see the Findings list, page 88.</p>
	View localisation	<p>If localisation is associated with a finding, a Localisation icon will display next to the finding name in the Findings List and a purple overlay will display on the image when you select the finding.</p> <p>For CTB studies, you can also use the Scroll thumb to scroll through the areas highlighted in purple on the Slice scrollbar.</p>					
	View laterality	<p>If laterality is associated with a finding, a Laterality icon will display next to the finding name in the Findings List and a purple arrow (or arrows) will display on the image when you select the finding.</p>					
Localisation does not display	<p>If the AI model indicates that a finding is present and its location is obvious to the clinician, localisation will not display for that finding (and the Localisation icon will not show in the Findings List).</p> <p>To check which findings display localisation, see the Findings list, page 88.</p>						
<p> The Localisation toggle must be switched on to view localisation or laterality. See Localisation toggle, page 66.</p>							
Return to the Results List	Click Results list above the Findings List to return to the Results List.						

Interpret the confidence level

A default confidence threshold for each finding will be provided for your organisation. For a finding to be considered present in the study, it must therefore have a score greater than this threshold.

For each finding, the AI model provides:



- a confidence score, and
- a 95% confidence interval.

This information is displayed on the Confidence bar in the Study Viewer.

See:

- [Confidence bar, page 66](#)
- [Confidence score, page 66](#)
- [Confidence threshold, page 66](#)
- [Confidence interval, page 66](#)

Refer to the following examples:

Confidence level	Interpretation
Higher confidence	<ul style="list-style-type: none"> • The confidence score is above the confidence threshold • Both confidence interval endpoints are above the confidence threshold • The AI model has a high confidence that the finding is present in the study 
Lower confidence	<ul style="list-style-type: none"> • The confidence score is above the confidence threshold • The lower endpoint of the confidence interval is below the confidence threshold • The AI model may have some uncertainty that the finding is present in the study 

Troubleshooting and support

Troubleshooting

Problems and solutions

If you have issues with the Annalise Enterprise application, refer to the following tables:

- [Error codes: Annalise Viewer, page 79](#)
- [Error codes: Annalise Web Viewer, page 82](#)
- [Other solutions: Annalise Viewer, page 83](#)
- [Other solutions: Annalise Secondary Capture, page 85](#)

If you are still unable to resolve the issue, contact the Annalise.ai Professional Services Team.

Error codes: Annalise Viewer

No.	Issue	Solution
001	Invalid ID or password.	Try signing in again using a valid ID and password. For further assistance, contact your internal IT support team and quote the error code.
002	Annalise Viewer version or licence is unsupported, or Annalise Viewer is blocked by firewall.	Contact your internal IT support team and quote the error code.
003	Annalise servers are currently unavailable.	
004	Annalise servers are currently offline.	Check your internet connection. If your internet connectivity is OK and the problem continues, contact your internal IT support team and quote the error code.
005	Either the study is not supported, or the study may not have reached the Annalise Integration Adapter. If the study was recently performed, it may not have been forwarded to Annalise Enterprise.	If the problem continues, contact your internal IT support team and quote the error code.
006	Annalise Enterprise only supports studies for patients who are: <ul style="list-style-type: none"> • 16 years or older (for CXR), or • 18 years or older (for CTB). Annalise Enterprise uses DICOM tags to determine age.	All findings are not available for this study.

No.	Issue	Solution
007 008	<p>The study does not meet minimum requirements for AI processing:</p> <ul style="list-style-type: none"> • Annalise Enterprise only supports studies containing chest X-rays or brain CT scans • the study must contain at least one PA or AP image or supported CT views (see Supported scan types, page 8) <p>Annalise Enterprise includes an AI feature that determines whether:</p> <ul style="list-style-type: none"> • the image is a chest X-ray or brain CT, and • if there is a PA or AP image or supported brain image. <p>AI models have an error margin. On rare occasions, Annalise Enterprise will not recognise a chest X-ray or brain CT and this error will display.</p>	<p>For further assistance, contact your internal IT support team and quote the error code.</p>
009 010 011	<p>An unexpected error occurred while analysing the study.</p>	<p>Contact your internal IT support team and quote the error code.</p>
014	<p>Annalise servers are currently unavailable.</p>	
015 016 020	<p>The study cannot be requested from Annalise servers.</p>	
021 022	<p>An unexpected error occurred while analysing the study.</p>	
023	<p>Study exceeds the allowed number of images per CXR study.</p>	
026	<p>The study cannot be requested from Annalise servers.</p>	
027	<p>Cannot connect to your PACS as the port is already in use.</p>	
029 030	<p>The study has not yet completed AI processing.</p>	<p>Wait for a few moments then try opening the study again.</p>
		<p>If the problem continues, contact your internal IT support team and quote the error code.</p>
031	<p>Unexpected error analysing study.</p>	<p>Contact your internal IT support team and quote the error code.</p>

No.	Issue	Solution
<p>032 033 034 035 036 037 038 039 040 041 042 043 044 045 046 047 048 049 050 051</p>	<p>The study does not meet the minimum requirements for AI processing:</p> <ul style="list-style-type: none"> • Annalise Enterprise only supports studies containing chest X-rays or brain CT scans • the study must contain at least one PA or AP image or supported CT views (see Supported scan types, page 8) <p>Annalise Enterprise includes an AI feature that determines whether:</p> <ul style="list-style-type: none"> • the image is a chest X-ray or brain CT, and • if there is a PA or AP image or supported brain image. <p>AI models have an error margin. On rare occasions, Annalise Enterprise will not recognise a chest X-ray or brain CT and this error will display.</p>	<p>For further assistance, contact your internal IT support team and quote the error code.</p>
<p>052</p>	<p>The application is currently undergoing maintenance (such as installing upgrades).</p>	<p>Once maintenance is complete, you will be able to use the application as normal.</p>
<p>053</p>	<p>The study does not meet the minimum requirements for AI processing:</p> <ul style="list-style-type: none"> • Annalise Enterprise only supports studies containing chest X-rays or brain CT scans • the study must contain at least one PA or AP image or supported CT views (see Supported scan types, page 8) <p>Annalise Enterprise includes an AI feature that determines whether:</p> <ul style="list-style-type: none"> • the image is a chest X-ray or brain CT, and • if there is a PA or AP image or supported brain image. <p>AI models have an error margin. On rare occasions, Annalise Enterprise will not recognise a chest X-ray or brain CT and this error will display.</p>	<p>For further assistance, contact your internal IT support team and quote the error code.</p>
<p>099</p>	<p>An unexpected error occurred while analysing the study.</p>	<p>Contact your internal IT support team and quote the error code.</p>

Error codes: Annalise Web Viewer

No.	Issue	Solution
J014	Annalise servers are currently unavailable.	Contact your internal IT support team and quote the error code.
J015	The study cannot be requested from Annalise servers.	
J016 J017	<p>The study does not meet minimum requirements for AI processing:</p> <ul style="list-style-type: none"> Annalise Enterprise only supports studies containing chest X-rays or brain CT scans the study must contain at least one PA or AP image or supported CT views (see Supported scan types, page 8) <p>Annalise Enterprise includes an AI feature that determines whether:</p> <ul style="list-style-type: none"> the image is a chest X-ray or brain CT, and if there is a PA or AP image or supported brain image. <p>AI models have an error margin. On rare occasions, Annalise Enterprise will not recognise a chest X-ray or brain CT and this error will display.</p>	For further details, contact your internal IT support team and quote the error code.
J018 J019 J020 J021 J022	An unexpected error occurred while analysing the study.	Contact your internal IT support team and quote the error code.
J027	<p>Annalise Enterprise only supports studies for patients who are:</p> <ul style="list-style-type: none"> 16 years or older (for CXR), or 18 years or older (for CTB). <p>Annalise Enterprise uses DICOM tags to determine age.</p>	AI findings are not available for this study.
J028	Study exceeds the allowed number of images per CXR study.	Contact your internal IT support team and quote the error code.
J032 J098 J099	An unexpected error occurred while analysing the study.	<p>Try to upload the study again.</p> <p>If the problem continues, contact your internal IT support team and quote the error code.</p>

No.	Issue	Solution
J101 J102 J103 J104 J105 J106 J107	The study does not meet minimum requirements for AI processing: <ul style="list-style-type: none"> Annalise Enterprise only supports studies containing chest X-rays or brain CT scans the study must contain at least one PA or AP image or supported CT views (see Supported scan types, page 8) 	For further details, contact your internal IT support team and quote the error code.
J108 J109	Annalise Enterprise includes an AI feature that determines whether:	
J110 J111 J112	<ul style="list-style-type: none"> the image is a chest X-ray or brain CT, and if there is a PA or AP image or supported brain image. 	
J113 J114 J115 J116 J117 J118	AI models have an error margin. On rare occasions, Annalise Enterprise will not recognise a chest X-ray or brain CT and this error will display.	

Other solutions: Annalise Viewer

Problem	Solution
Missing server settings Organisation details are incomplete.	Contact your internal IT support team.
Application unresponsive After loading a study in the PACS viewer, the Annalise Viewer does not respond.	<p>Follow these steps:</p> <ol style="list-style-type: none"> 1. Check that the study is a CR (Computed Radiography), DX (Digital Radiography) or CT brain. 2. Go to your taskbar and click the Desktop Peek area twice. 3. Quit the Annalise Viewer, then open it again. 4. Attempt to re-load the study. <p>If the problem persists, contact your internal IT support team.</p>
Application unresponsive with Sectra PACS The Annalise Viewer is unresponsive when a study is loaded. Sectra PACS warns that the viewer is out of sync.	<p>Follow these steps:</p> <ol style="list-style-type: none"> 1. Ensure the Annalise Viewer Adapter is running in the System Tray. 2. Ensure the Sectra Desktop Sync functionality is enabled. 3. Quit then restart the Annalise Viewer Adapter. <p>If required, contact your internal IT support team for assistance.</p>
Unexpected finding change When viewing a study, the AI findings change unexpectedly.	<p>Some software systems may encounter this error when viewing studies in multiple windows.</p> <p>The Annalise Viewer will synchronise with the currently selected window.</p> <p>Ensure that the shortcut key mapping in the PACS viewer is mapped correctly.</p>

Problem	Solution
<p>Annalise Viewer not visible</p> <p>When launching Annalise Enterprise, the Annalise icon displays in your taskbar, but the Annalise Viewer does not display.</p>	<p>Follow these steps:</p> <ol style="list-style-type: none"> 1. Navigate to the following location: <ul style="list-style-type: none"> • for Windows (via File Explorer): %APPDATA%\Annalise • for Mac (via Finder): <i>Macintosh HD/Users/{user}/Library/Application Support/Annalise</i> 2. Delete the Preferences file.

Other solutions: Annalise Secondary Capture

Problem	Root cause	Steps to resolve
There is no Secondary Capture series available	<p>Any of the following may have occurred:</p> <ul style="list-style-type: none"> • the study may still be processing • the study may be out of scope • the study might not have reached the Annalise Enterprise Integration Adapter • there might be a connectivity issue or a technical product error • if the study was performed recently, it might not have been forwarded to Annalise Enterprise 	<p>Wait a few moments then check whether the Secondary Capture series displays in the PACS.</p> <p>If the series still doesn't display, check that the study meets all the criteria for processing.</p> <p>See:</p> <ul style="list-style-type: none"> • Contraindications, page 4 • Supported scan types, page 8 <p>If the problem persists, contact your internal IT support team.</p>
One or more images in the Secondary Capture series is missing	<p>There could be a connectivity issue, or a technical product error may have occurred.</p>	<p>Wait a few moments then check whether the Secondary Capture series displays in the PACS.</p> <p>If the problem persists, contact your internal IT support team.</p>
Not all images in the study are present in the Secondary Capture result	<p>Not all source images in the study have been routed to the Annalise Integration Adapter.</p> <p>Annalise Secondary Capture results will only be sent for the first successfully completed AI result.</p> <p>If further images arrive after the first prediction is triggered, the new Secondary Capture results will not be sent to the PACS.</p>	<p>Contact your internal IT support team.</p>

Support

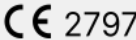


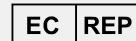



Support and feedback

Refer to the following table for support and feedback details:

Support type	Details
Professional services, technical support, product feedback and complaints	Email support@annalise.ai Any serious incidents related to the device/s should be reported to Annalise.ai, and where applicable, the competent authority or regulatory authority in which the user and/or patient is established.
Product user, performance and administration guides	Check our website: annalise.ai/guides

Symbol glossary

Definitions of symbols that may appear on the Annalise Enterprise device or in the related documentation are listed below.

Symbol	Information
	CE labelling
	Manufacturer
	Medical device
	European Authorised Representative
	Swiss Authorised Representative
	Indicates a warning or caution
	Read the instructions for use

Appendices

Findings list

Overview

The clinical development of the Annalise CXR and Annalise CTB ontology trees enabled Annalise Enterprise to identify a comprehensive list of radiological findings that would be most clinically necessary and helpful to clinicians.

These findings are referred to as the 'findings list'.

For information on the performance of the AI model, refer to the *Annalise Enterprise Performance Guide*.

Annalise CXR findings list

The Annalise CXR findings list is outlined below.

CXR finding	Definition	Localisation
Abdominal clips	Surgical clips in the abdomen.	No
Acute clavicle fracture	Cortical breach of a clavicle. May be difficult to see if nondisplaced. No callus formation for acute fractures.	Yes
Acute humerus fracture	Cortical breach of the humerus; usually at the surgical neck of the humerus.	Yes
Acute rib fracture	Cortical breach of a rib without callus formation or union. Does not include surgical rib resection or thoracotomy.	Yes
Airway stent	Stents within the trachea or bronchi.	No
Aortic arch calcification	Calcification of the aortic arch. Does not include mitral valve calcification, descending aortic or pericardial calcification. Only includes Grade 2 or Grade 3 calcification (i.e. thick calcification).	No
Aortic stent	Stent/graft in the aorta.	No
Atelectasis	Includes subsegmental collapse, linear and bibasal atelectasis.	Yes
Axillary clips	Surgical clips in the axilla.	Yes
Basal interstitial thickening	Opacities within pulmonary lobules in a linear/branching pattern affecting predominantly lower zones of one or both lungs. Also includes thickened chronic fibrotic changes from lung scarring. May still be predicted if there are upper-zone changes as long as the pattern is lower-zone predominant.	Yes
Biliary stent	Stents within the biliary tree.	No
Breast implant	Breast prosthesis, usually of gel-like material implanted behind or in place of the female breast, as cosmetic or reconstructive surgery.	No
Bronchiectasis	Dilation of the bronchi. Can be localised or diffuse.	No

CXR finding	Definition	Localisation
Calcified axillary nodes	Calcified soft tissue density in the axilla.	No
Calcified granuloma (< 5 mm)	Calcified intraparenchymal lesion (or lesions) which are smaller than 5 mm.	No
Calcified hilar lymphadenopathy	Calcified lymph nodes in hilum.	No
Calcified mass (> 5 mm)	One or more intraparenchymal lesions (> 5 mm) which may be partially or completely calcified.	Yes
Calcified neck nodes	Calcified soft tissue density in the neck.	No
Calcified pleural plaques	Calcified thickening along the pleura at the diaphragm, lateral thoracic wall or apex.	No
Cardiac valve prosthesis	Replacement of native cardiac valve. Includes transcatheter aortic valve implantation.	No
Cavitating mass(es)	Lucent walled lesion which arises from a solid lesion that then develops gas within it. As a result, the wall is typically thickened.	Yes
Cavitating mass with content	Collection of air with air fluid level or in crescent shape that separates the wall of a cavity from an inner mass.	Yes
Cervical flexion	The chin is visible and obscuring the apex of the lung or superior mediastinum. Only the primary AP or PA view is assessed, not the lateral view or any other view/post-processed image.	No
Chronic clavicle fracture	Corticated clavicle fractures with surrounding callus formation or union.	No
Chronic humerus fracture	United, malunited or non-united humerus fracture.	No
Chronic rib fracture	Cortical breach of a rib with surrounding callus formation or union.	No
Clavicle fixation	Internal fixation of clavicle fractures. When a fracture has been fixed, the acute clavicle fracture may not be predicted.	Yes
Clavicle lesion	Sclerotic or lytic, malignant or benign lesion within the clavicle with or without pathological fracture. Includes lesions due to systemic conditions such as myeloma, osteogenesis imperfecta and renal osteodystrophy.	Yes
Coronary stent	Stents within the coronary arteries.	No
Diaphragmatic elevation	Left hemidiaphragm is higher than the right, or the right hemidiaphragm is more than 3 cm higher than the left. Only applies to the inspiratory view, not the lateral or expiratory views.	No
Diaphragmatic eventration	Abnormal contour of the diaphragm affecting only a segment of the hemidiaphragm.	No

CXR finding	Definition	Localisation
Diffuse airspace opacity	Diffuse ill-defined airspace/ground glass opacity or consolidation throughout one or both lungs.	Yes
Diffuse bullae	Multiple large lucencies due to emphysema in the upper and lower zones of one or both lungs.	No
Diffuse fibrotic volume loss	Opacities within pulmonary lobules in a linear/branching pattern affecting one or both lungs. Upper and lower zones affected. Associated with volume loss (hilar displacement, diaphragmatic elevation, tracheal displacement). Also includes thickened chronic fibrotic changes from lung scarring.	Yes
Diffuse interstitial thickening	Opacities within pulmonary lobules in a linear/branching pattern affecting both upper and lower zones of one or both lungs. Also includes thickened chronic fibrotic changes from lung scarring.	Yes
Diffuse lower airspace opacity	Diffuse ill-defined airspace/ground glass opacity or consolidation in predominantly the lower zones of one or both lungs. Does not include interstitial opacities. May still be predicted if there are upper-zone changes as long as the pattern is lower-zone predominant.	Yes
Diffuse nodular/miliary lesions	Multiple tiny lung opacities of one or both lungs. Usually innumerable and too small to measure. May be calcified.	Yes
Diffuse pleural thickening	Pleural masses/opacities in multiple locations. Pleural mass is distinguished from intraparenchymal mass by having an obtuse angle with the pleura.	No
Diffuse spinal osteophytes	Flowing osteophytes at the anterior or right lateral vertebral body connecting at least four contiguous vertebrae. Typically, smooth and thin connections.	No
Diffuse upper airspace opacity	Diffuse ill-defined airspace/ground glass opacity or consolidation in predominantly the upper zones of one or both lungs. Does not include interstitial opacities. May still be predicted if there are lower-zone changes as long as the pattern is upper-zone predominant.	Yes
Distended bowel	Pathologically distended small or large bowel loops or stomach. Small bowel loops should measure > 3 cm and large bowel loops > 6 cm, or the stomach causes mass effect upon the diaphragm. Air fluid levels may be present on erect view.	No
Electronic cardiac devices	Pacemakers, pacing wires (internal or external), internal defibrillators and loop recorders. ECG leads do not count as electronic cardiac devices.	No
Focal airspace opacity	Single area of consolidation or air space/ground glass opacity in the lung. Air bronchogram may be present.	Yes

CXR finding	Definition	Localisation
Gallstones	Calcified RUQ stones projected over the gallbladder.	No
Gastric band	Band around the gastro-oesophageal junction.	No
Hiatus hernia	Sliding or paraoesophageal hiatus hernia into the posterior mediastinum. Retrocardiac fluid level may be present.	No
Hilar lymphadenopathy	Increase in size and density of the hila with loss of normal hilar angle.	No
Humeral lesion	Sclerotic or lytic, malignant or benign lesion within the humerus with or without pathological fracture. Includes lesions due to systemic conditions such as myeloma, osteogenesis imperfecta and renal osteodystrophy.	Yes
Hyperinflation	Increased total lung volumes as evidenced by flattening of the diaphragm or increased retrosternal clear space on lateral view (or both).	No
Image obscured	Image obscured by object.	No
Incompletely imaged chest	Part of the lungs not included in the image. May be predicted if any image in the series is incomplete.	No
Inferior mediastinal mass	Masses within the mediastinum with the centre of the mass below the superior border of the aortic arch.	No
In position CVC	Internal jugular lines, subclavian lines and peripheral inserted catheters (PICC). Central venous lines should be placed with the tip in the SVC/cavoatrial junction. The line should not be in the brachiocephalic, subclavian veins, or right atrium.	Yes
In position ETT	Endotracheal or tracheostomy tube within the trachea for ventilation. Needs to be 3 cm to 7 cm above the carina.	No
In position NGT	Enteric tube from the mouth/nose into the stomach for feeding or drainage.	Yes
In position PAC	Pulmonary artery catheter with tip within the pulmonary artery or main pulmonary trunk.	No
Intercostal drain	This finding could mean either of the following: <ul style="list-style-type: none"> Malpositioned intercostal drain: ICC with tip or side holes not within the pleural cavity; typically migrates out into the soft tissue In-position intercostal drain: Catheter within the pleural space to drain fluid and/or gas 	Yes
Internal foreign body	Non-surgical internal foreign bodies, such as inhaled foreign bodies or gunshot shrapnel, that are internal to the patient.	Yes
Kyphosis	Increased kyphosis of the thoracic spine with Cobb angle greater than 45 degrees on lateral view. Usually predicted off the lateral view.	No

CXR finding	Definition	Localisation
Loculated effusion	Fluid within the pleural cavity that is trapped within a fissure or at the apex or lateral wall on an erect view.	Yes
Lower zone bullae	Multiple large lucencies due to emphysema in the lower zones of one or both lungs. May still be predicted if there are upper-zone changes as long as the pattern is lower-zone predominant.	No
Lower zone fibrotic volume loss	Opacities within pulmonary lobules in a linear/branching pattern affecting one or both lungs. Lower zone predominant. Associated with volume loss (diaphragmatic elevation). Also includes thickened chronic fibrotic changes from lung scarring. May still be predicted if there are upper-zone changes as long as the pattern is lower-zone predominant.	Yes
Lung collapse	Collapse of the entire lung or most of the lung.	Yes
Lung sutures	Suture material within the lung parenchyma, which is typically post lung resection.	No
Mastectomy	Absence or asymmetry of breast shadows suggesting mastectomy or partial mastectomy.	No
Mediastinal clips	Surgical clips in the mediastinum or hilum. Typically, small clips from coronary artery bypass grafts. Hilar clips from lung surgery also fall under this category.	No
Multifocal airspace opacity	Multiple areas of ill-defined airspace/ground glass opacity or consolidation.	Yes
Multiple masses or nodules	More than one pulmonary mass/nodule.	Yes
Neck clips	Any surgical clips in the neck.	Yes
Nipple shadow	Rounded well-defined density projected over the expected locations of the nipple; sometimes bilateral.	No
Oesophageal stent	Stents within the oesophagus.	No
Osteopaenia	Severe reduced apparent bone density of the vertebrae such that there is difficulty distinguishing between bone and adjacent soft tissues, even when windowing appropriately. Usually predicted off the lateral view.	No
Overexposed	Unable to see lung markings even after appropriate windowing. Only the primary AP or PA view is assessed, not the lateral view or any other view/post-processed image.	No
Patient rotation	The spinous process is laterally displaced by more than a quarter of the interclavicular distance. Only the primary AP or PA view is assessed, not the lateral view or any other view/post-processed image. If the patient is severely scoliotic, this finding may be unreliable.	No

CXR finding	Definition	Localisation
Pectus carinatum	Congenital chest wall deformity with anterior protrusion of the sternum.	No
Pectus excavatum	Congenital chest wall deformity with concave depression of the sternum.	No
Peribronchial cuffing	Thickening of the bronchial wall without dilation of the bronchial lumen.	No
Pericardial fat pad	Fat pad adjacent to the heart border. Can be mistaken for consolidation by referrers.	No
Perihilar airspace opacity	Diffuse perihilar airspace/ground glass opacity of one or both lungs. Does not include interstitial opacities. Can still be predicted if there are other changes as long as the pattern is perihilar predominant.	Yes
Pleural mass	Pleural mass/opacity in one location. Pleural mass is distinguished from intraparenchymal mass by having an obtuse angle with the pleura. A pleural mass is either nodular thickening of the pleura or pleural thickening greater than 1 cm. The pleural mass should affect less than half the lung height and is unilateral. Local pleural thickening less than 1 cm is usually ignored.	Yes
Pneumomediastinum	Gas within the mediastinum, typically outlining the pericardium and mediastinal margin.	No
Post resection volume loss	Volume loss due to resection of lung (e.g. pneumonectomy, lobectomy or segmentectomy) usually with staples/clips visible.	Yes
Pulmonary artery enlargement	Enlargement of the pulmonary artery typically with loss of the aortopulmonary window. Width of the right descending pulmonary artery > 17 mm on the PA film.	No
Pulmonary congestion	Upper lobe diversion with loss of tapering of vessels towards the apices with upper zone vessels having similar or larger diameter compared with lower zone. Only reliable on erect views.	No
Reduced lung markings	Reduced lung markings.	No
Rib fixation	Internal fixation of rib fractures. May not be predicted if the fracture has been fixated.	Yes
Rib lesion	Sclerotic or lytic, malignant or benign lesion within the rib with or without pathological fracture. Includes lesions due to systemic conditions such as myeloma, osteogenesis imperfecta and renal osteodystrophy. Congenital rib anomalies such as bifid or fused ribs are not included.	Yes

CXR finding	Definition	Localisation
Rib resection	Surgical removal of ribs (may be multiple). Typically, thoracotomies are performed for lung resection.	No
Rotator cuff anchor	Bone anchors within the humeral heads.	Yes
Scapular fracture	Cortical breach of the scapula. Includes both acute and chronic fractures.	Yes
Scapular lesion	Sclerotic or lytic, malignant or benign lesion within the scapula with or without pathological fracture. Includes lesions due to systemic conditions such as myeloma, osteogenesis imperfecta and renal osteodystrophy.	Yes
Scoliosis	Increased lateral curvature of the thoracic spine with Cobb angle greater than 10 degrees on frontal view.	No
Segmental collapse	Collapse of entire segment or lobe of the lung, or compressive collapse from adjacent pleural effusion.	Yes
Shoulder arthritis	Loss of joint space, osteophyte formation, sclerosis and degenerative changes of the glenohumeral joint. Usually only predicted if there are significant changes, i.e. near-complete loss of joint space.	No
Shoulder dislocation	Humeral head not articulating with glenoid fossa. Typically anterior and inferior dislocation.	Yes
Shoulder fixation	Internal fixation of humerus or scapula fractures. May not be predicted if the fracture has been fixated.	Yes
Shoulder replacement	Total, partial or reverse total shoulder replacement.	Yes
Simple effusion	Fluid within the pleural cavity. In an erect radiograph this accumulates at the base. May form a meniscus.	Yes
Simple pneumothorax	Air within the thoracic cavity outside of the lung. May be associated with lung edge.	Yes
Solitary lung mass	Single rounded well-defined opacity. Measures 3 cm or larger.	Yes
Solitary lung nodule	Single rounded well-defined opacity. Measures less than 3 cm.	Yes
Spinal arthritis	Near-complete loss of intervertebral space, fusion of vertebrae, or heavy calcification of intervertebral discs at multiple levels.	No
Spinal fixation	Internal fixation of the spine for fractures or degeneration.	No
Spinal lesion	Sclerotic or lytic, malignant or benign lesion within the thoracic spine with or without pathological fracture. Includes lesions due to systemic conditions such as myeloma, osteogenesis imperfecta and renal osteodystrophy.	Yes

CXR finding	Definition	Localisation
Spinal wedge fracture	<p>Acute or chronic compression, wedge, distraction or translated fractures. Typically seen on lateral view.</p> <p>Usually, chronicity cannot be reliably assessed so this is not differentiated.</p> <p>For compression or wedge fractures, there should be more than 20% loss in anterior height or central height as measured to the nearest normal vertebra or posterior vertebral body height (whichever is larger).</p>	Yes
Sternotomy wires	Metallic wires fixating a sternotomy.	No
Subcutaneous emphysema	<p>Air within the soft tissues outside the abdominal or thoracic cavity.</p> <p>May be associated with pneumothorax or pneumomediastinum.</p>	Yes
Subdiaphragmatic gas	Gas below the diaphragm not contained within a lumen.	No
Suboptimal CVC	CVC or PICC line where the tip of the catheter is not positioned at the cavoatrial junction or the distal SVC, or if the catheter is looped or kinked.	Yes
Suboptimal ETT	Endotracheal or tracheostomy tube that is either too close to the carina or too far from it (not within 3 cm to 7 cm), or is within a bronchus.	No
Suboptimal gastric band	<p>Band around the gastro-oesophageal junction with phi angle between the band and the spine not within 0 to 60 degrees.</p> <p>Malpositioned bands may be associated with oesophageal dilation.</p>	No
Suboptimal NGT	<p>NGT where the tip and the side holes are not projected within the stomach, or the tip of the NGT is not visible and the image is cut off within 5 cm of the gastro-oesophageal junction.</p> <p>May be within the oesophagus or bronchus.</p>	Yes
Suboptimal PAC	Pulmonary artery catheter with tip not in the main pulmonary trunk or pulmonary arterial branch (e.g. in the right ventricle), or if the catheter is looped or kinked.	No
Superior mediastinal mass	<p>Masses within the mediastinum with the centre of the mass above the superior border of the aortic arch/loss of paratracheal stripes.</p> <p>If the patient is supine or rotated, the superior mediastinum can be widened due to benign causes such as venous distension or projection.</p>	No
Tension pneumothorax	<p>Air within the thoracic cavity outside of the lung.</p> <p>May be associated with lung edge. Resultant mediastinal shift.</p>	Yes
Tracheal deviation	<p>Moving of the trachea across to one side secondary to increased pressure on one side or decreased pressure on the other side.</p> <p>Consideration of the extent of patient rotation must be taken into account.</p>	No

CXR finding	Definition	Localisation
Underexposed	Outline of any thoracic vertebral bodies not visible. Only the primary AP or PA view is assessed, not the lateral view or any other view/post-processed image.	No
Underinflation	The diaphragm is projected above the ninth posterior rib in a PA view or above the seventh rib in an AP view.	No
Unfolded aorta	Widening of the aortic curve while maintaining a normal aortic diameter.	No
Upper interstitial thickening	Opacities within pulmonary lobules in a linear/branching pattern affecting predominantly upper zones of one or both lungs. Also includes thickened chronic fibrotic changes from lung scarring. Can still be predicted if there are lower-zone changes as long as the pattern is upper-zone predominant.	Yes
Upper zone bullae	Multiple large lucencies due to emphysema in the upper zones of one or both lungs. May still be predicted if there are lower-zone changes as long as the pattern is upper-zone predominant.	No
Upper zone fibrotic volume loss	Opacities within pulmonary lobules in a linear/branching pattern affecting one or both lungs. Upper zone predominant. Has associated volume loss (hilar elevation). Also includes thickened chronic fibrotic changes from lung scarring. Includes apical scarring (e.g. from previous TB). Can still be predicted if there are lower-zone changes as long as the pattern is upper-zone predominant.	Yes
Widened aortic contour	Widening of the aortic arch diameter to 4.5 cm or greater, or the descending aorta to 4 cm or greater, typically due to aneurysm, dissection or rupture.	No
Widened cardiac silhouette	Increased cardiothoracic ratio > 0.5 on PA view and > 0.6 on AP view. Includes cardiomegaly and enlarged cardiac silhouette due to pericardial effusion.	No

Annalise CTB findings list

The Annalise CTB findings list is outlined below.

CTB finding	Definition	Localisation
Abnormal prominent vessels	Prominence of vessels in the brain or along the surface of the brain, consistent with a vascular malformation. May contain haemorrhage.	Yes
Acute brainstem infarct	Acute hypodensity of brainstem (within two weeks).	Yes
Acute cerebellar infarct	Hypodensity of cerebellum in vascular distribution or with history consistent with acute infarct. Subacute infarct is also included if under two weeks old or maintains mass effect. Does not include old infarcts.	Yes
Acute cerebral infarct	Acute infarct in any cerebral artery territory secondary to thrombo-embolism, vasospasm, vascular compression or dissection.	Yes
Acute haemorrhagic infarct	Acute infarct in any cerebral artery territory containing frank haemorrhage.	Yes
Acute infarct petechial haemorrhage	Acute infarct in any cerebral artery territory containing petechial haemorrhage.	Yes
Acute intraparenchymal haemorrhage	Acute haematoma (hyperdense) in the cerebral hemispheres (including basal ganglia and periventricular), brainstem or cerebellum.	Yes
Acute lacunar infarct	Mild ill-defined hypodensity of basal ganglia, thalami or deep white matter consistent with acute lacunar infarct. Does not include old lacunar infarcts.	Yes
Acute on chronic subdural haematoma	Mixture of hyperdense and hypodense crescent-shaped subdural haematoma extending over the cortical surface of the brain.	Yes
Acute peripheral infarct	Small acute hypodensities of cortex or subcortical white matter due to small infarcts, usually from a central embolic cause or fragmented emboli from large vessel.	Yes
Acute subdural/extradural haematoma	Hyperdense crescent-shaped haematoma extending over the cortical surface of the brain.	Yes
Acute watershed infarct	Acute infarct in deep and/or superficial watershed distributions between vascular territories, usually from thrombo-embolic disease, global hypotension or vasospasm.	Yes
Aggressive bone lesion	Lytic bone lesion in calvarium with favoured aggressive appearances (wide zone of transition, aggressive periosteal reaction).	Yes
Aggressive extra-axial mass of soft tissue	Aggressive mass in the extra-axial space, typically a Grade II or Grade III meningioma, haemangiopericytoma or dural metastasis. Invades into skull or causes aggressive periosteal reaction.	Yes

CTB finding	Definition	Localisation
Aggressive meningeal thickening	Localised or nodular dural thickening, greater than 5 mm in thickness. May be associated with vasogenic oedema. Includes leptomeningeal carcinomatosis.	Yes
Aggressive skin lesion	Soft tissue density thickening of the scalp or skin in face or neck with aggressive features such as osseous invasion.	Yes
Air fluid level paranasal sinuses	Acute fluid collection or blood in the paranasal sinuses.	No
Aneurysm	Rounded density in the region of a vessel, consistent with an aneurysm.	Yes
Aneurysm coils	Metallic coils placed within the lumen of an aneurysm.	No
Arachnoid cyst	Subdural or extradural collection of CSF density (e.g. arachnoid cyst or pseudomeningocele, or epidermoid cyst).	Yes
Basal ganglia and dentate calcification	Calcification of the basal ganglia and dentate nuclei, usually physiological, due to aging but can be pathological (e.g. metabolic disorders or Fahr's disease). Usually only predicted if more than four small specks, each of size > 3 mm, or at least one single larger speck > 5 mm in length.	No
Cerebellar atrophy	Prominent cerebellar fissures and enlarged fourth ventricle due to volume loss of cerebellar parenchyma disproportionate to the patient's age.	No
Cerebral atrophy	Prominent sulci and enlarged ventricles due to volume loss of cerebral parenchyma.	No
Cerebral convexity subarachnoid haemorrhage	Hyperdensity in subarachnoid space of the cerebral convexity sulci.	Yes
Chiari malformation	Cerebellar tonsillar ectopia extending 5 mm or more below foramen magnum.	Yes
Chronic globe abnormality	Elongation of the globe due to scleral thinning (staphyloma) or protrusion of the globe through scleral defect (coloboma). Shrunken globe due to phthisis bulbi is also included in this finding.	Yes
Chronic or fungal sinusitis	Signs that indicate chronic or fungal infection of the sinus, i.e. calcification or hyperdensity within the mucosal opacity or thickening of the walls of the sinus.	No
Chronic subdural haematoma	Hypodense crescent-shaped CSF dense collection extending over the cortical surface of the brain. Includes subdural hygromas.	Yes
Cochlear implant	Electronic device with electrode implanted into the basal turn of cochlea to treat deafness.	No
Colloid cyst	A hyperdense or isodense cyst abutting the anterior roof of the third ventricle.	Yes

CTB finding	Definition	Localisation
Colpocephaly	A descriptive term for a disproportionate prominence of the occipital horns of the lateral ventricles. It can result from a wide range of congenital insults (in particular, callosal agenesis).	No
Communicating hydrocephalus/NPH	Enlargement of the ventricular system involving all ventricles, without evidence of ventricular obstruction.	No
Corpus callosum agenesis/hypogenesis	Complete or partial absence of the corpus callosum due to developmental anomaly.	No
Cortical laminar necrosis	Gyriform hyperdensity (may be calcification or blood products) due to chronic cortical death, usually secondary to hypoxic/ischaemic insult. Associated with thinning of the cortex. Often associated with encephalomalacia.	No
Cortical or leptomeningeal calcification	Gyriform calcific density in the cortex. Can be secondary to old infarcts or congenital lesions like Sturge Weber, or post infectious causes.	No
Craniotomy/cranioplasty/craniectomy	Removal of calvarial bone. Includes replacement of calvarial bone by bone or implant. Also includes burr holes.	No
Craniotomy extra-axial collection	Collection of fluid or haematoma deep to the craniotomy site, commonly seen post craniotomy.	No
Deep brain stimulation electrodes	Electrodes extending through frontal lobes to basal ganglia, subthalamus or brainstem for treating movement disorders such as Parkinson's Disease.	No
Deep white or grey matter infarct	Small old hypodensity in periventricular white matter, lentiform nuclei, caudate, thalami, brainstem > 15 mm. Due to old infarct in distribution of the perforating vessels.	No
Diffuse hypoxic-ischaemic encephalopathy	Generalised swelling of the gyri and loss of sulcal space. Can have loss of grey-white matter differentiation, or reversal of grey and white matter attenuation. Includes metabolic insults like methanol poisoning.	No
Dilated superior ophthalmic vein	Dilated superior ophthalmic vein of greater than 4 mm diameter involving the whole length of the vessel within the orbit. May also be hyperdense due to thrombus.	Yes
Disappearing basal ganglia sign	Obscuration of basal ganglia due to reduced density in the setting of an acute MCA infarct.	Yes
Dural calcification	Calcification of the dura due to chronic haematoma or infection. Does not include physiological calcification of the falx.	No
Effacement of basal cisterns	Obscuration of the basal cisterns (e.g. suprasellar cistern or cisterna magna), due to mass effect caused by intra-axial or extra-axial lesions.	No
Empty sella	Pituitary fossa is largely empty of tissue. Often associated with expanded pituitary fossa.	No

CTB finding	Definition	Localisation
Encephalomalacia	Focal loss of brain parenchymal volume due to chronic insult.	No
Entrapment of lateral ventricle	Enlargement of a portion of the lateral ventricle due to compression proximally by mass effect. Typically, entrapment occurs in the temporal horn of a lateral ventricle.	Yes
Erosion of bone in tympanic cavity	Erosion of the walls of the tympanic cavity, the ossicles or scutum as seen with cholesteatoma or tumours.	Yes
Exophthalmos	Greater than 23 mm protrusion of the anterior surface of the globe beyond the interzygomatic line.	Yes
Expanded pituitary fossa	Enlargement of the pituitary fossa greater than 17 mm in length and 13 mm in height. Includes erosion of the dorsum sellae due to expanded sella from long-standing raised ICP.	No
Extracranial herniation	Brain herniation external to the inner table of the skull.	No
Extracranial Ventricular Drain (EVD)	Surgically placed drain, usually positioned in the anterior horn of a lateral ventricle, to reduce intraventricular pressure or surgically placed tubing to measure the intraventricular pressure.	No
Extradural haematoma	Biconvex, lens-shaped haematomas, often constrained by cranial sutures.	Yes
Face and neck haematomas	Haematoma in the neck or face which may be due to recent trauma or surgery.	No
Focal intra-axial calcification	Foci of calcification within the cerebral hemispheres, brainstem or cerebellum. May be a vascular lesion, such as a cavernoma, or chronic infection, such as cysticercosis.	Yes
Foreign body face and neck	Non-surgical foreign body in the soft tissues of the neck or face. Does not include surgically implanted devices or lines, or subcutaneous calcifications.	Yes
Foreign body orbit	Non-surgical foreign body in the orbit. Does not include surgically implanted devices or lines, or subcutaneous calcifications.	Yes
Foreign body scalp	Non-surgical foreign body in the soft tissues of the scalp. Does not include surgically implanted devices or lines, or subcutaneous calcifications.	Yes
Fourth ventricular effacement	Effacement, narrowing or compression of fourth ventricle due to mass effect.	No
Fracture of calvarium	Acute fracture line through the calvarium. Also includes suture diastasis secondary to trauma.	Yes
Fracture of skull base	Fracture involving the base of skull. Includes fractures of the occipital condyles.	Yes

CTB finding	Definition	Localisation
Fracture paranasal sinuses/ facial bones	Acute fracture of the facial bones including orbits, paranasal sinuses, nasal bone, maxilla, mandible. Fractures that have surgical fixation, even if recent, come under the definition of 'sino-nasal surgery'.	Yes
Generalised calvarial thickening	Bone density is increased throughout the calvarium. Includes thickening of calvarium due to Paget's or medication.	No
Haemorrhagic contusion	Hyperdense blood within a brain contusion due to head trauma. Common sites include the anterior frontal and temporal lobes.	Yes
Haemorrhagic lesion in sella	Haematoma in the sella and/or suprasellar region. Usually caused by haemorrhage into a pituitary adenoma often associated with pituitary apoplexy. Pituitary mass may be evident and may be hyperdense. Fluid-debris levels may also be evident. Also includes haematoma post transsphenoidal surgery.	Yes
Hyperdense artery in anterior circulation	Density consistent with clot in the lumen of the middle or anterior cerebral artery or branches.	Yes
Hyperostosis frontalis	Benign overgrowth of the inner table of the frontal bone, more common in women over 65 years of age. Nodular bony formations on the inner table, protruding greater than 1 cm in thickness beyond the adjacent normal component of the calvarium.	No
Hypopneumatized mastoid	Bone is present in the mastoid instead of air cells. The lack of pneumatized mastoid air cells is usually congenital or due to childhood mastoiditis.	No
Insular ribbon sign	Hypodensity of insular cortex, obscuring the border with the external capsule, in the setting of an acute MCA infarct.	Yes
Intraaxial lesion calcification	Any partially calcified mass lesion within the cerebrum, cerebellum or brainstem. Also applies to a cyst or mass that has a calcified component or wall.	Yes
Intraaxial lesion complex cyst	Complex cyst within the cerebrum, cerebellum or brainstem (not CSF). May have adjacent oedema.	Yes
Intraaxial lesion haemorrhage	Any mass lesion within the cerebrum, cerebellum or brainstem containing haemorrhage. Any intraaxial lesion can have 'intraaxial lesion haemorrhage' as an additional finding. Does not include haemorrhagic infarct or intraparenchymal haemorrhage with no underlying lesion.	Yes
Intraaxial lesion heterogeneous	Heterogeneous mass lesion within the cerebrum, cerebellum or brainstem with hypodense or hyperdense or isodense components.	Yes
Intraaxial lesion hyperdense	Homogeneous hyperdense cerebral, cerebellar or brainstem mass (e.g. due to lymphoma).	Yes

CTB finding	Definition	Localisation
Intraaxial lesion hypodense	Homogeneous hypodense mass lesion within the cerebrum, cerebellum or brainstem. The density of the mass is relative to normal brain parenchyma (not the adjacent vasogenic oedema).	Yes
Intraaxial lesion isodense	Cerebral, cerebellar or brainstem mass, homogeneous and isodense relative to the surrounding brain parenchyma. The density of the mass is relative to normal brain parenchyma (not the adjacent vasogenic oedema).	Yes
Intra-ocular silicone	Intra-ocular injection of silicone (hyperdense) for treatment of retinal detachment.	Yes
Intraventricular haemorrhage	Acute haemorrhage (hyperdense) within the ventricular system. Causes fluid/fluid levels, usually seen in posterior horns of lateral ventricles. Can be due to trauma, hypertension or haemorrhagic lesions.	Yes
Left/right ventricular effacement	Effacement, narrowing or compression of lateral ventricle due to mass effect.	Yes
Mastoidectomy	Any type of mastoidectomy or surgery to petrous temporal bones.	Yes
Mastoid opacification	Partial or complete opacification of the mastoid air cells, typically secondary to fracture, mastoid effusion or mastoiditis.	No
Meningioma with hyperostosis of adjacent calvarium	Meningioma with hyperostosis of adjacent calvarium.	Yes
Metallic artefact	Streaking artefact (called beam hardening artefact) due to the presence of metallic density object in the field of image acquisition (e.g. braces or external frame).	No
Midline shift	Subfalcine herniation or displacement of the medial cerebral hemisphere or displacement of the mid cerebellum laterally by greater than 2 mm.	Yes
Movement artefact	Artefact causing blurring and obscuration of the image due to motion of the patient during the scan.	No
Mucosal thickening	Greater than 5 mm thickening of mucosa (over a length of more than 10 mm) in the paranasal sinuses. Includes sino-nasal polyposis, mucosal retention cysts and polyps.	No
Non-aggressive extra-axial mass containing calcification	Meningioma containing areas of calcification.	Yes
Non-aggressive extra-axial mass without calcification or fat	Meningioma without aggressive features.	Yes
Non-aggressive skin lesion	Non-aggressive soft tissue lump in the scalp including sebaceous or epidermal cysts.	Yes
Obstructive hydrocephalus	Enlargement of one or more ventricles due to obstruction.	No

CTB finding	Definition	Localisation
Old lacunar infarct	Small old hypodensity in lentiform nuclei, caudate, thalami, brainstem or periventricular white matter greater than 2 mm and less than 15 mm in diameter.	No
Opacity in tympanic cavity	Opacification of the middle ear cavity due to middle ear effusion, haemotympanum, chronic otitis media or cholesteatoma.	Yes
Orbital fat stranding	Ill-defined fat stranding in the orbit. May be due to orbital cellulitis or retro-orbital haemorrhage.	Yes
Orbital mass benign	Well-defined soft tissue mass or cystic lesion in the orbit (intra and extraconal) separate to the extra-ocular muscles. Includes vascular lesions and optic nerve sheath meningiomas.	Yes
Orbital mass inflammatory or malignant	Orbital mass which is ill-defined and may involve one or more extra-ocular muscles (in which case it usually involves the myotendinous junction). May have associated fat stranding.	Yes
Osteoma	Homogenous sclerotic benign lesion which can be in paranasal sinuses or skull vault.	Yes
Parotid lesion	Solid or cystic parotid lesions.	Yes
Perimesencephalic/ aneurysmal subarachnoid haemorrhage	Hyperdensity in subarachnoid space of the basal cisterns, interhemispheric fissure or sylvian fissures.	Yes
Petrous bone fracture	Fracture of the petrous temporal bones. Often longitudinal or transverse.	Yes
Pineal mass or complex cyst	Mass, cystic mass or complex cyst within the pineal region with soft tissue component greater than 1 cm in width and length.	Yes
Pneumocephalus	Subarachnoid, subdural or extradural collection of air density or intraventricular air.	Yes
Prominent perivascular spaces	CSF density spaces typically found below the basal ganglia at the anterior commissure level.	No
Prosthetic globe	Fabricated replacement of the globe in the orbit.	Yes
Resection cavity	Acute/subacute surgical resection cavity following excision of a mass which may contain blood, fluid or gas.	Yes
Scalp haematomas	Haematoma in the scalp, usually due to recent trauma or surgery. Includes post-surgical collection superficial to craniotomy.	No
Sella or suprasellar cyst, mass or cystic mass	Cyst, cystic/solid or solid mass in sella or suprasellar region. Includes pituitary tumours, Rathke's cleft cysts, suprasellar tumours and abnormal thickening of the pituitary stalk from inflammatory conditions (hypophysitis).	Yes
Simple pineal cyst	Simple cyst within the pineal region greater than 1 cm in diameter.	Yes

CTB finding	Definition	Localisation
Sino-nasal, oral, mandibular and maxillofacial surgery	Evidence of previous sino-nasal surgery such as maxillary antrostomies or ethmoidal clearance and fixation of facial bone fractures.	No
Sinus soft tissue density lesion	Soft tissue density lesion in the sinus, secondary to organising haematoma or cancer.	No
Small vessel ischaemic disease	Chronic hypodensity in the white matter (often confluent), typically in the periventricular or deep white matter.	No
Soft tissue mass in the neck	Any soft tissue mass in the neck or infratemporal fossa including abscesses/masses at the fossa of Rosenmuller, oral and nasopharyngeal cavity masses, enlarged (> 1.5 cm short axis) or necrotic lymphadenopathy. Includes extra-osseous extension of bony lesions into the soft tissue, soft tissue mass in the face and calcified nodes in the neck.	Yes
Striatocapsular slit-like chronic haemorrhage	Small old slit-like hypodensity in lentiform nuclei, caudate, thalami, brainstem or periventricular white matter resulting from a previous hypertensive bleed.	No
Subacute intraparenchymal haemorrhage	Subacute haematoma (4 to 21 days, usually isodense), in the cerebral hemispheres, including basal ganglia, periventricular white matter, brainstem or cerebellum. Not due to cerebral contusion or an underlying lesion.	Yes
Subacute subdural haematoma	Isodense crescent-shaped haematoma extending over the cortical surface of the brain.	Yes
Subcutaneous emphysema	Air within subcutaneous tissues usually due to fractured paranasal sinuses, ruptured larynx or trachea, penetrating injury or extension of subcutaneous emphysema from the chest.	No
Subependymal calcification or nodules	Calcification of the subependymal tissues < 1 cm. Usually calcified subependymal nodules are associated with tuberous sclerosis. Also includes non-calcified subependymal nodules due to tuberous sclerosis.	No
Sulcal effacement	Effacement, narrowing or compression of sulci due to mass effect.	No
Temporomandibular joint arthritis	Narrowing of the temporomandibular joint space and osteophyte formation or erosions.	No
Temporomandibular joint dislocation	Dislocation or subluxation of the temporomandibular joint.	Yes
Third ventricular effacement	Effacement, narrowing or compression of third ventricle due to mass effect.	No
Tonsillar herniation	Downward extension of the cerebellar tonsils through the foramen magnum due to raised intracranial pressure.	Yes
Transependymal oedema	Hypodensity along ventricular walls due to increased pressure from hydrocephalus, most commonly seen adjacent to the frontal and occipital horns of the lateral ventricles.	No

CTB finding	Definition	Localisation
Transphenoidal surgery	Surgical resection performed through the sphenoid sinus, typically for resection of sellar or suprasellar lesions.	No
Uncal herniation	Downward herniation of the inferior medial temporal lobe through the incisura of the cerebellar tentorium.	Yes
Vascular clips	Surgical clips placed on vessels within the skull cavity. Includes aneurysmal clips. Does not include craniotomy clips or other clips outside the cranial vault.	No
Vasogenic oedema	Deep white matter hypodensity extending into subcortical white matter.	Yes
Ventricular cyst/ xanthogranulomatous change	CSF density cyst within the ventricles > 1 cm diameter. Includes choroid plexus lesions such as xanthogranulomatous cysts.	Yes
Ventricular mass	Cystic/solid intraventricular mass. Includes choroid plexus lesions such as choroid plexus lipoma.	Yes
Ventriculoperitoneal (VP) shunt	Tubing extending from ventricles to the peritoneal cavity to treat hydrocephalus. Tubing typically passes through the parietal lobe into the body of the lateral ventricle.	No
Vitreous haemorrhage	Hyperattenuation in the vitreous chamber (which may be either homogeneous or heterogeneous).	Yes



OPT-PRM-027 Annalise Enterprise User Guide (DOC-1422) Ver. 7

Approved By:

Kim Cross - Author

June 7, 2024 10:10 PM AEST

afd0bfce-f580-410c-b890-10cb8c27a7f0

Rohan James - Document Control

June 10, 2024 10:30 AM AEST

cca0da08-1108-4fab-9945-aad7f0bb1621

Chrishan Fernando - Reviewer

June 11, 2024 2:39 PM AEST

c843a17d-40c3-44fa-ac14-ed3d0bf937bb

Daryl Fong - Reviewer

June 12, 2024 1:21 PM AEST

3d876d26-d1d9-4d37-84f2-47a89838d75e

Pravindhya Gajadeera - Regulatory

June 12, 2024 2:40 PM AEST

0579ffce-b86c-4bcf-956c-fde0796f70b8

Version History:

Author	Effective Date	Ver.	Status
Kim Cross	June 12, 2024 4:14 PM AEST	7	Published
Kim Cross	April 16, 2024 11:48 AM AEST	6	Superseded
Kim Cross	February 22, 2024 2:38 PM AEDT	5	Superseded
Kim Cross	December 15, 2023 10:03 AM AEDT	4	Superseded
Kim Cross	August 31, 2023 3:12 PM AEST	3	Superseded
Kim Cross	April 17, 2023 10:37 AM AEST	2	Superseded
Kim Cross	July 28, 2022 2:00 PM AEST	1	Superseded
Kim Cross	April 26, 2022 11:56 AM AEST	0	Superseded